

Chapter 8

Surgical Management of Class C and D Tympanojugular Paragangliomas

Sampath Chandra Prasad, Paolo Piazza, Alessandra Russo, Abdelkader Taibah, Francesco Galletti, and Mario Sanna

Introduction

Tympanojugular paragangliomas (TJPs) have always presented a challenge to surgeons due to the fact that these tumors are vascular and locally aggressive and involve important neurovascular structures like the jugular bulb (JB), the internal carotid artery (ICA), and the facial and the lower cranial nerves (LCNs, CN IX, X, XI, XII). Owing to their indolent nature, they often present late with cranio-temporo-cervical extensions rendering them inoperable in the past. However, significant developments in the last couple of decades have changed this scenario. A thorough anatomical and surgical mapping of the skull base and descriptions of various rational approaches, in addition to technological improvements in neuromonitoring, neuroanesthesia, and neuroradiology, have made surgical removal of skull base tumors technically feasible and safer. Fisch originally classified TJPs into classes A, B, C, and D according to location and extension based on high-resolution computed tomography (HRCT) examination. This was subsequently modified by Sanna [1] to include subclassifications and an additional class V to include tumors that involve the vertebral artery (VA) (Table 8.1).

TJPs, being trans-cranio-temporo-cervical in nature, demand that the surgeon has a thorough understanding of skull base anatomy and surgical techniques for

S.C. Prasad (✉) • A. Russo • A. Taibah • M. Sanna
Department of Neurotology and Skull Base Surgery, Gruppo Otologico, Piacenza-Rome, Italy
e-mail: sampathcp@gmail.com

P. Piazza
Department of Neuroradiology, University of Parma, Parma, Italy

F. Galletti
Faculty of Medicine and Surgery, Azienda Ospedaliera Universitaria Di Messina, Messina, Italy

Table 8.1 Modified Fisch classification of the temporal bone paragangliomas (TBPs)

Tympanomastoid paragangliomas (TMPs)	Class A	Tumors confined to the middle ear	
		A1	Tumor margins clearly visible on otoscopic examination
		A2	Tumor margins not visible on otoscopy. Tumors may extend anteriorly to the Eustachian tube and/or to the posterior mesotympanum
	Class B	Tumors confined to the tympanomastoid cavity without destruction of bone in the infralabyrinthine compartment of the temporal bone	
		B1	Tumors involving the middle ear with extension to the hypotympanum
		B2	Tumors involving the middle ear with extension to the hypotympanum and the mastoid
		B3	Tumors confined to the tympanomastoid compartment with erosion of the carotid canal
Tympanojugular paragangliomas (TJPs)	Class C	Tumors extending beyond the tympanomastoid cavity, destroying bone of the infralabyrinthine and apical compartment of the temporal bone, and involving the carotid canal	
		C1	Tumors with limited involvement of the vertical portion of the carotid canal
		C2	Tumors invading the vertical portion of the carotid canal
		C3	Tumors with invasion of the horizontal portion of the carotid canal
		C4	Tumors reaching the anterior foramen lacerum
	Class D	Tumors with intracranial extension	
		De1	Tumors up to 2 cm dural displacement
		De2	Tumors with more than 2 cm dural displacement
		Di1	Tumors up to 2 cm intradural extension
		Di2	Tumors with more than 2 cm intradural extension
	Class V	Tumors involving the VA	
		Ve	Tumors involving the extradural VA
		Vi	Tumors involving the intradural VA

effectively dealing with them. Surgical management of TJPs has steadily yielded better results over the last couple of decades after the description of the infratemporal fossa (ITFA) type A approach by Fisch and colleagues [2] and the addition of extensions to it [3, 4]. The introduction of techniques like intra-arterial stenting of the ICA at our center in 2003 has made surgery possible even in cases that were previously considered inoperable. However, surgery in this complex region is still fraught with danger, requiring the ability to accurately assess varied interrelated factors, their impact on the ultimate result, and their management. In this chapter, we summarize the various techniques and refinements in skull base surgery and neuroradiology that can be used to yield very satisfactory results in the management of C1 to C4 TJPs.

Choosing the Right Approach to the Jugular Fossa

The jugular fossa is a highly complex anatomical area closely related to critical neurovascular structures. To achieve optimal exposure while minimizing its morbidity is the goal of all skull base surgeries. To obtain proximal and distal exposure of the major vessels is an important basic principle in the management of all vascular tumors [5–7]. This dictum above all should determine the degree of exposure required in the management of TJPs, due to their invariable involvement of the ICA.

Two critical points to consider when obtaining adequate surgical exposure are whether the facial nerve (FN) needs mobilization and whether the middle ear can be preserved. These issues form the core argument in the treatment of jugular fossa pathology. It is not the intracranial extension that is the primary consideration that has to be taken into account while selecting an approach, but the degree and nature of ICA involvement. Most of the documented approaches that avoid FN rerouting limit the degree of exposure of the intrapetrous ICA and certainly limit any ability to safely remove bone around this vessel, which is usually required in the management of C2–C4 TJP. For alternate pathologies of the jugular fossa, more “conservative” approaches in relation to both the FN and middle ear structures can often be utilized.

This ITFA type A has been the mainstay of surgery for TJPs ever since it was described by Fisch and Pillsbury in 1979 [8]. The ITFA type A is designed to allow access to the jugular foramen area, the infralabyrinthine and apical compartments of the petrous bone, the vertical segment of the internal carotid artery, and the upper jugulocarotid space (Fig. 8.1a). The approach is designed primarily for extensive extradural lesions involving these areas. The key point in this approach is the anterior transposition of the FN to provide optimal control of the targeted areas (Fig. 8.1b). The other structures that prevent lateral access to these areas are shown in Fig. 8.1c. Besides the FN they include the tympanic bone, the digastric muscle, and the styloid process. These structures are removed to allow an unhindered lateral access. The morbidity associated with the classic ITFA type A includes conductive hearing loss, temporary or permanent FN dysfunction due to permanent anterior rerouting of the nerve, and temporary masticatory difficulties.

In the recent past, many authors have favored the technique of retaining the FN in situ without rerouting it in the ITFA type A and/or attempt to conserve the external auditory canal in the resection of jugular fossa tumors [9–16]. Unfortunately, however, these reports often do not clearly differentiate between vascular and non-vascular tumors nor do they discuss the stage of the paragangliomas treated. It is the involvement of the intratemporal ICA and the infiltrative nature of the pathology that dictates the surgical approach. While it is true that some smaller tumors could be removed this way [17], it is incorrect to apply the principle for all classes of TJPs. The involvement of the intratemporal ICA and the infiltrative nature of the pathology must dictate the surgical approach. Hypotympanic approaches to small C1 tumors are employed by some surgeons for minimal jugular fossa involvement, but the risk of limited ICA exposure and the lack of proximal and distal control of the

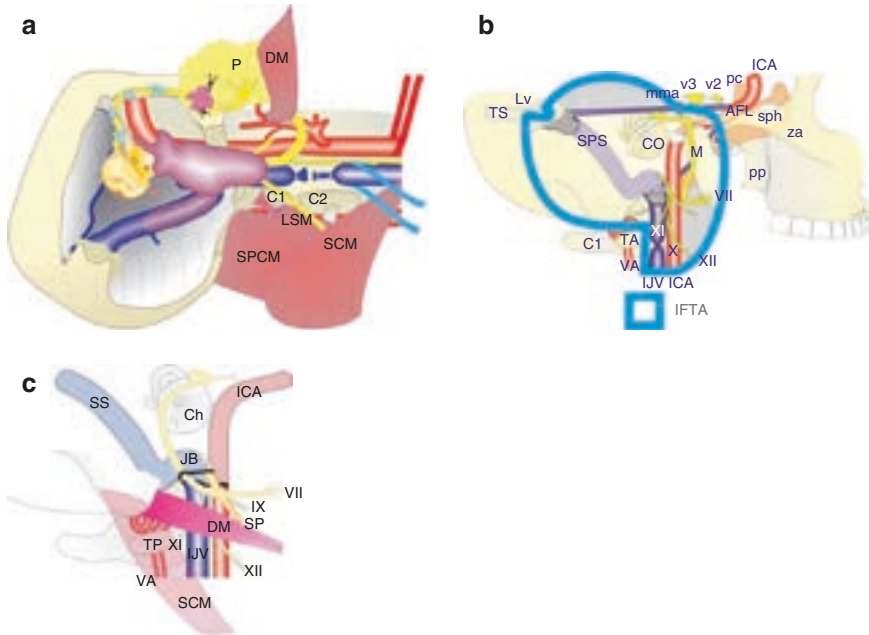


Fig. 8.1 Illustrations for ITFA type A. **(a)** An illustration of surgical view in ITFA. **(b)** An illustration of surgical limit in ITFA. **(c)** An illustration of obstacles to approach the jugular bulb. *ICA* internal carotid artery, *sph* sphenoid sinus, *za* zygomatic arch, *pc* clinoid process, *V2* maxillary branch of trigeminal nerve, *V3* mandibular branch of trigeminal nerve, *pp*. pterygoid plate, *M* mandible, *Co* cochlea, *sps* superior petrosal sinus, *Lv* vein of Labbe, *TS* transverse sinus, *ev* emissary vein, *OC* occipital condyle, *TA* transverse process of atlas, *C1* atlas, *C2* axis, *VA* vertebral artery, *VII* FN, *IX* glossopharyngeal nerve, *XI* spinal accessory nerve, *XII* hypoglossal nerve, *IJV* internal jugular vein, *FN* facial nerve, *TP* transverse process of the atlas, *DM* posterior belly of the digastric muscle, *SCMM* sternocleidomastoid muscle, *SP* styloid process, *JB* jugular bulb, *Co* cochlea, *SpCM* splenius capitis muscle, *LSM* levator scapulae muscle, and *P* parotid gland

jugulosigmoid system can be significant [18–21]. The assertion that a purely infralabyrinthine approach, with preservation of the middle ear and the FN left in situ, is a safe and effective approach for most TJP is erroneous as limited anterosuperior exposure creates the risk of residual tumor and the potential for catastrophic injury to the ICA. These approaches that are essentially a variation of the petro-occipital trans-sigmoid approach certainly have their indications and are suitable for addressing minimally invasive and minimally vascularized jugular fossa pathology. They can also be considered for early class C1 TJPs, with predominantly posterior disease, and class B3 tumors [22]. The majority of TJPs, which are in close proximity to the ICA, require an ITFA to facilitate safe removal of the tumor [22, 23]. Circumferential dissection of the FN in its vertical segment with preservation of a thin bony coverage is referred to as a fallopian bridge technique [23, 24]. This technique allows access to the jugular bulb on either side of the FN [25] and can be applied with either preservation or elimination of the EAC and middle ear structures

[23]. However, this technique still limits anterior control, and there remains a small risk of FN injury due to possible fracture of the fallopian bridge.

FN mobilization also allows safe removal of the styloid process and complete removal of the tympanic bone, which is invariably infiltrated in TJP. This would provide for optimal control of the upper parapharyngeal space, the ICA, and the LCN. The true results of facial function following rerouting must be analyzed in comparison to tumor recurrence rates and associated morbidity when the FN is not mobilized. We strongly feel that the relatively mild facial dysfunction associated with anterior rerouting from the geniculate ganglion is a small price to pay for improved access which provides definitive vascular control and ultimately reduces recurrence rates [2].

A purely retrosigmoid approach that is commonly used to manage LCN schwannomas and posterior fossa meningiomas does not allow safe removal of tumor that extends into the jugular foramen and is therefore a common cause for recurrence. Hence a transjugular approach is usually necessary in the management of jugular foramen pathology and is essential to allow excision of lesions that have true extension into the jugular foramen and further down into the parapharyngeal space [26]. It is generally in the rare case where sacrifice of the jugulosigmoid system is not possible as detected on preoperative assessment, in which conservative measures like a retrosigmoid approach may be considered.

Preservation of the jugulosigmoid system has been also described for jugular fossa pathology, when it has been compressed but not invaded. The suprajugular approach, essentially a presigmoid and infralabyrinthine approach, involves dissection of the infralabyrinthine air cell tract, with an opening of the dura between the labyrinth and the jugular bulb, allowing improved access up to the jugular foramen [27]. The pneumatization pattern of the temporal bone plays a large role in the amount of room that can be gained in this area. Evidently, while preservation of the jugulosigmoid system has been described for dumbbell tumors of the LCN [28], this might not allow complete removal of the tumor. As mentioned, a transjugular approach is usually necessary in management of JF pathology and is essential to allow excision of lesions that have true extension into the jugular foramen and further into the parapharyngeal space [26]. It is only in the rare case where sacrifice of the jugulosigmoid system is not possible as detected on preoperative assessment, in which these more conservative measures should be considered.

The use of the far or extreme lateral approaches with various extensions has been proposed for accessing the jugular fossa to preserve the middle ear and leave the FN in situ and even avoidance of drilling the petrous bone at all [10, 13, 15, 29–33]. It must be remembered that the far-lateral approach was initially developed to access lesions of the craniocervical junction and ventral lower brain stem in order to limit brain stem retraction and pathology without significant involvement of the temporal bone [27, 30, 34, 35]. However, this approach by itself limits the control of the intrapetrous carotid and the ability to widely remove infiltrated bone. The real advantage in this approach lies in improved exposure of the intradural extension. In summary these techniques are useful adjuncts to the ITFA, especially in C2–C4 tumors.

The subtemporal-infratemporal approach was initially described by Sekhar for the removal of extradural lesions of the mid to upper clivus and involvement of the petrous ICA [36]. It is a preauricular approach that, when used in isolation, represents an anterior approach to the jugular fossa. While it avoids the necessity to reroute the FN, it requires resection of the mandibular condyle and mobilization of the petrous ICA and gives limited exposure to the bony margins of the jugular fossa. It has no role as a sole approach for lesions of the jugular fossa. In combination with an IFTA, it is essentially the same as an ITFA type B and is employed to control the area medial to the horizontal intrapetrous ICA [5, 37]. The classic ITFA type A is the most favored approach for class C1 and certain class C2 tumors, and the ITFA type A with extensions can be used to manage class C2–C4 tumors.

Rationale of the Infratemporal Fossa Approach Type A

This approach is designed to allow access to the jugular foramen area, the infralabyrinthine and apical compartments of the petrous bone, the vertical segment of the internal carotid artery, and the upper jugulocarotid space. The approach is designed primarily for extensive extradural lesions involving these areas. The key point in this approach is the anterior transposition of the FN to provide optimal control of the targeted areas. The other structures that prevent lateral access to these areas are shown in Fig. 8.1c. Besides the FN they include the tympanic bone, the digastric muscle, and the styloid process. These structures are removed to allow an unhindered lateral access.

Surgical Steps

A postauricular skin incision is performed (Fig. 8.2). A small, anteriorly based musculoperiosteal flap is elevated to help in closure afterward. The external auditory canal is transected and closed, and the FN is identified at its exit from the temporal bone

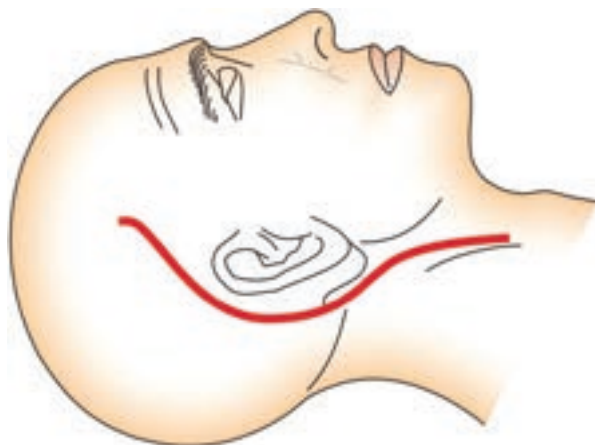


Fig. 8.2 Incision for infratemporal fossa approach type A

(Figs. 8.3 and 8.4). The main trunk is found at the perpendicular bisection of a line joining the cartilaginous pointer to the mastoid tip. The main trunk is traced in the parotid until the proximal parts of the temporal and zygomatic branches are identified. The posterior belly of digastric muscle and the sternocleidomastoid muscle are divided close to their origin. The internal jugular vein and the external and internal carotid arteries are identified in the neck. The vessels are marked with umbilical tape. The skin of the external auditory canal, the tympanic membrane, the malleus, and the incus is removed. A canal wall down mastoidectomy is performed, with removal of the bone anterior and posterior to the sigmoid sinus. The FN is skeletonized from the stylomastoid foramen to the geniculate ganglion. The last shell of bone is removed using a double-curved raspator. The suprastructure of the stapes is preferably removed after cutting its crura (Fig. 8.5). The inferior tympanic bone is widely removed, and the mastoid tip is amputated using a rongeur. A new fallopian canal (arrow) is drilled in the root of the zygoma superior to the Eustachian tube (Fig. 8.6). The FN is freed at the level of the stylomastoid foramen using strong scissors. The soft tissues at this level are not separated from the nerve (Fig. 8.7). The mastoid segment is next elevated using a Beaver knife to cut the fibrous attachments between the nerve and the fallopian canal. The tympanic segment of the nerve is elevated carefully, using a curved

Fig. 8.3 Exposure of Infratemporal Fossa Approach Type A after blind sac closure of the external auditory canal. *DM* digastric muscle, *EAC* external auditory canal, *ECA* external carotid artery, *FN* facial nerve, *ICA* internal carotid artery, *IX* glossopharyngeal nerve, *XI* spinal accessory nerve, *XII* hypoglossal nerve

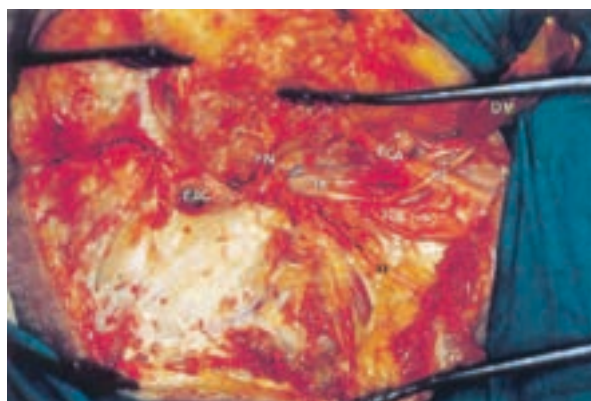

Fig. 8.4 The facial nerve is identified at the stylomastoid foramen. *EAC* external auditory canal, *FN* facial nerve

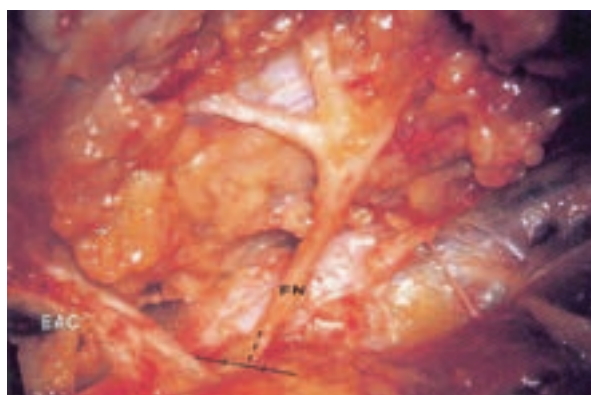


Fig. 8.5 The tympanic and mastoid segments of the facial nerve are skeletonised. *FN* facial nerve, *PFD* posterior fossa dura, *LSC* lateral semicircular canal, *psc* posterior semicircular canal, *ssc* superior semicircular canal, *StF* stylomastoid foramen

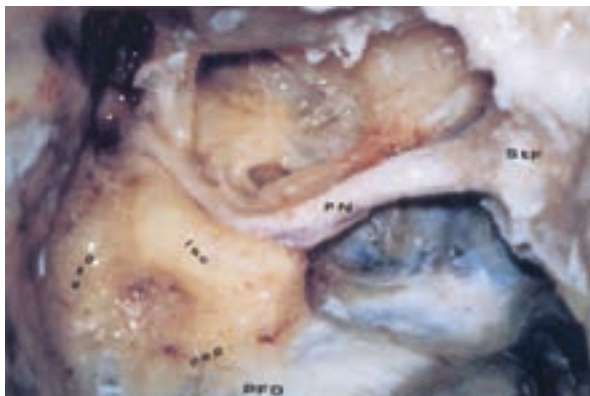


Fig. 8.6 The facial nerve from the geniculate ganglion to the terminal branches in the parotid are skeletonised. *Co* cochlea, *FN* facial nerve, *JB* jugular bulb, *PFD* posterior fossa dura, *LSC* lateral semicircular canal, *psc* posterior semicircular canal, *StF* stylomastoid foramen

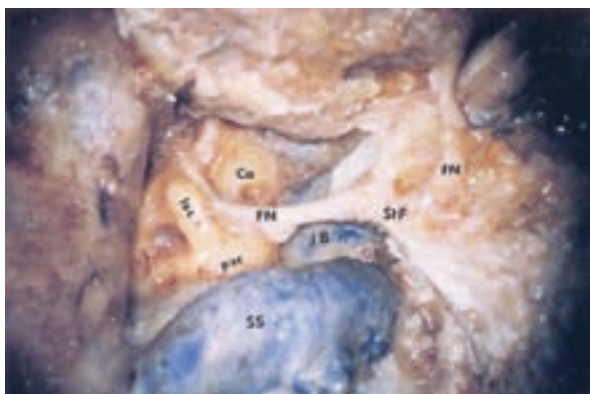
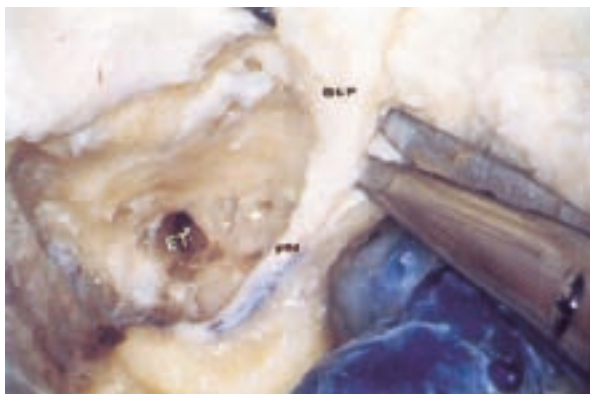


Fig. 8.7 The facial nerve is released at the stylomastoid foramen. *ET* Eustachian tube, *FN* facial nerve, *StF* stylomastoid foramen



raspatory, until the level of the geniculate ganglion is reached. A non-toothed forceps is used to hold the soft tissue surrounding the nerve at the stylomastoid foramen, and anterior rerouting is carried out (Fig. 8.8). A tunnel is created in the parotid gland to secure the transposed nerve (Fig. 8.9). The tunnel is dosed around the nerve using two

Fig. 8.8 The facial nerve is carefully elevated from its canal. *ET* Eustachian tube, *FN* facial nerve, *JB* jugular bulb, *LSC* lateral semicircular canal, *psc* posterior semicircular canal, *SS* sigmoid sinus

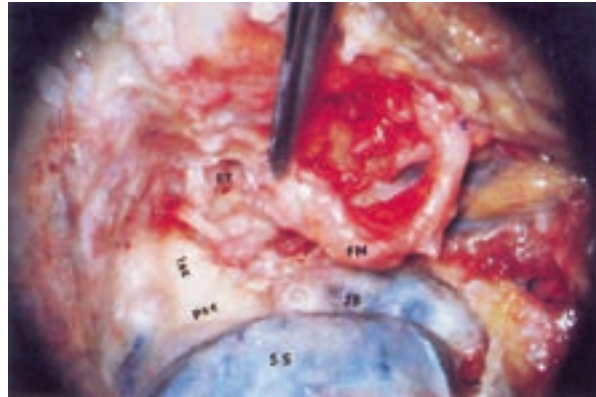


Fig. 8.9 The facial nerve is re-routed by stitching the cuff of tissue at the stylomastoid foramen to the parotid gland. *ET* Eustachian tube, *FN* facial nerve, *IJV* internal jugular vein, *JB* jugular bulb, *LSC* lateral semicircular canal, *psc* posterior semicircular canal, *SS* sigmoid sinus

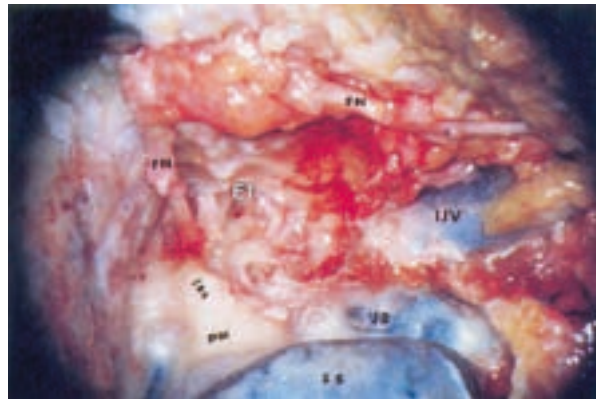
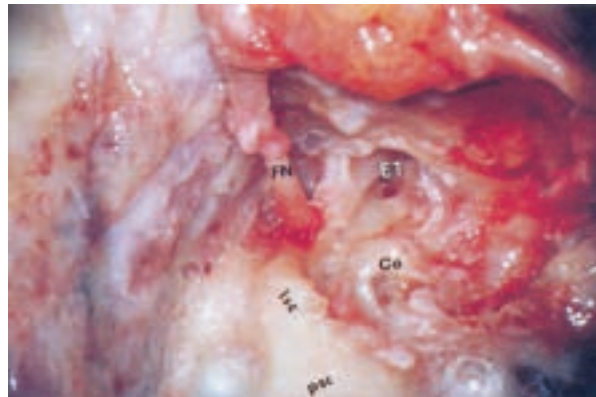

Fig. 8.10 The nerve is glued to the canal created for it at the root of the zygoma. *Co* cochlea, *ET* Eustachian tube, *FN* facial nerve, *LSC* lateral semicircular canal, *psc* posterior semicircular canal



sutures. A closer view shows the FN in its new bony canal, just superior to the Eustachian tube. The nerve is fixed to the new bony canal using fibrin glue (Fig. 8.10). Drilling of the infralabyrinthine cells is completed, and the vertical portion of the

internal carotid artery is identified (Fig. 8.11). The mandibular condyle is separated from the anterior wall of the external auditory canal using a large septal raspatory. The Fisch infratemporal fossa retractor is applied, and the mandibular condyle is anteriorly displaced, with care being taken not to injure the FN. The anterior wall of the external auditory canal is further drilled, thus completing the exposure of the vertical portion of the internal carotid artery. A small incision is made in the posterior fossa dura just behind the sigmoid sinus, through which an aneurysm needle is passed. Another incision is made just anterior to the sinus to allow for the exit of the needle (Fig. 8.12). The sinus is closed by double ligation with a Vicryl suture (Fig. 8.13). Suture closure of the sinus, however, may lead to gaps in the dural incision, with a higher risk of cerebrospinal fluid leakage postoperatively. Alternatively, the sigmoid sinus can be closed with Surgicel extraluminal packing (Fig. 8.14). The structures attached to the styloid process are severed. The styloid is fractured using a rongeur and is then cut with strong scissors (Figs. 8.15 and 8.16). The remaining tough fibrous tissue surrounding the internal carotid artery at its ingress into the skull base is carefully removed using

Fig. 8.11 The hypotympanic bone and the petrous bone below the cochlea is drilled out. *Co* cochlea, *FN* facial nerve, *ICA* internal carotid artery, *IJV* internal jugular vein, *JB* jugular bulb, *LSC* lateral semicircular canal, *psc* posterior semicircular canal, *SS* sigmoid sinus

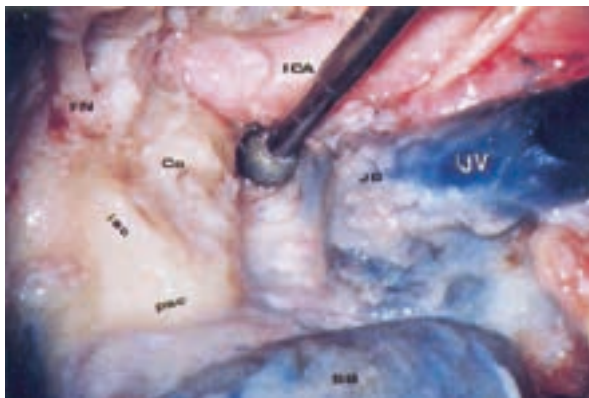

Fig. 8.12 The sigmoid sinus is completely skeletonised and a proximal control is achieved. *Co* cochlea, *FN* facial nerve, *ICA* internal carotid artery, *JB* jugular bulb, *PFO* posterior fossa dura, *psc* posterior semicircular canal, *sps* superior petrosal sinus, *SS* sigmoid sinus

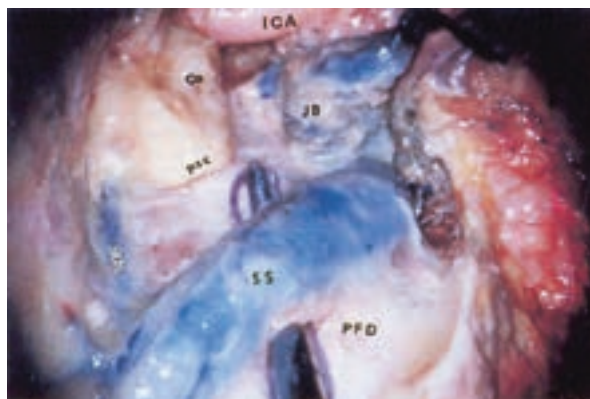


Fig. 8.13 The sigmoid sinus is ligated. *JB* jugular bulb, *LSC* lateral semicircular canal, *PFO* posterior fossa dura, *psc* posterior semicircular canal, *sps* superior petrosal sinus, *SS* sigmoid sinus

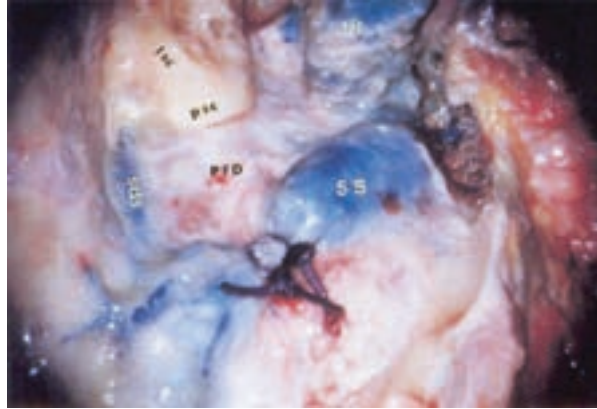


Fig. 8.14 Another technique is to achieve a sigmoid sinus closure is to do an extra and intra-luminal packing. *MFP* middle fossa plate, *S* Surgicel, *SS* sigmoid sinus, *IJV* internal jugular vein

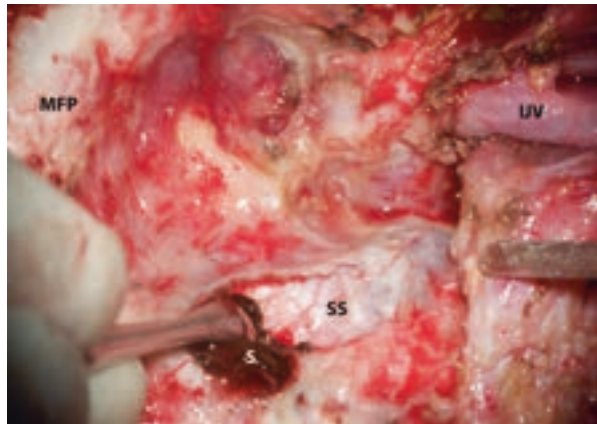


Fig. 8.15 The styloid process is identified and excised from its muscular attachments. *IJV* internal jugular vein, *SP* styloid process

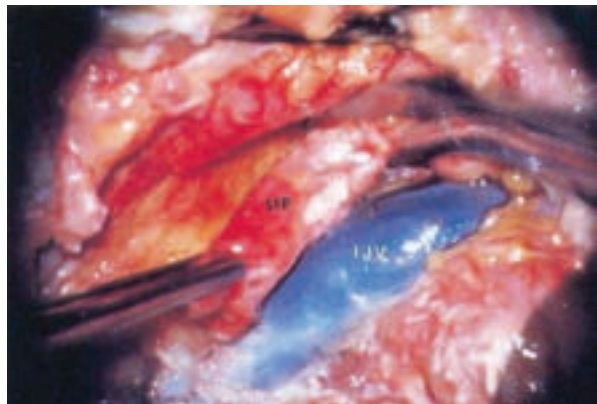


Fig. 8.16 The field after removal of the styloid process. *FN* facial nerve, *ICA* internal carotid artery, *IJV* internal jugular vein, *JB* jugular bulb, *IX* glossopharyngeal nerve

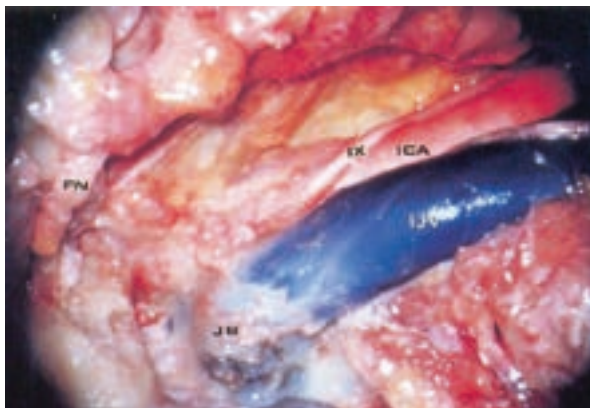


Fig. 8.17 The internal carotid artery is skeletonised at the carotid foramen drilling all around the vertical portion of the petrous carotid artery. *Co* cochlea, *FN* facial nerve, *ICA* internal carotid artery, *IJV* internal jugular vein, *IX* glossopharyngeal nerve

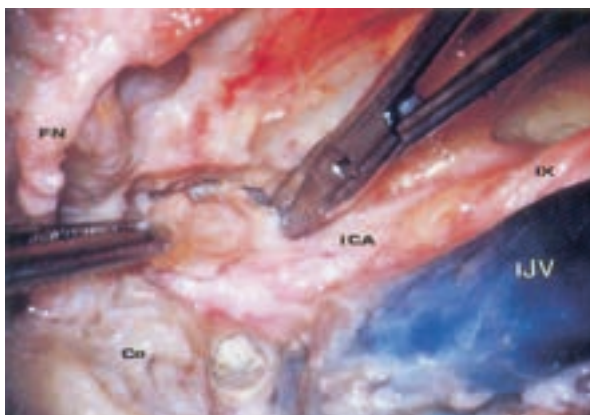
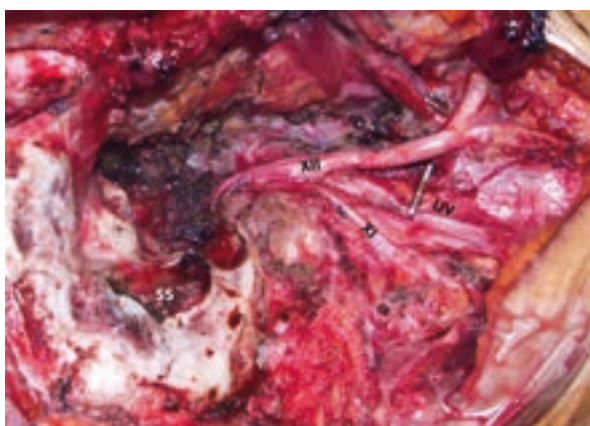


Fig. 8.18 The surgical field exposing the area of the tumor. *XI* spinal accessory nerve, *XII* hypoglossal nerve, *IJV* internal jugular vein, *SS* sigmoid sinus



scissors (Fig. 8.17). The internal jugular vein in the neck is double ligated and cut or closed with vascular clips (Fig. 8.18). The vein is elevated superiorly, with care being taken not to injure the related lower cranial nerves (Figs. 8.19 and 8.20). In cases in which the 11th nerve passes laterally, the vein has to be pulled under the nerve

Fig. 8.19 The transtuberular transcondylar extension. *ACV* anterior condylar vein, *FN* facial nerve, *ICA* internal carotid artery, *JB* jugular bulb, *LSC* lateral semicircular canal, *OC* occipital condyle, *psc* posterior semicircular canal, *SS* sigmoid sinus, *ssc* superior semicircular canal

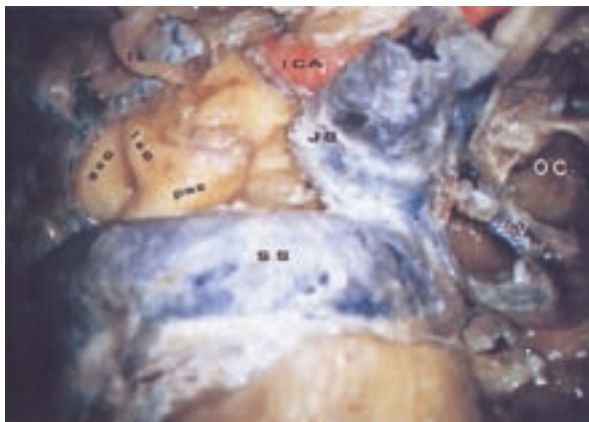


Fig. 8.20 The lower cranial nerves on the medial wall of the jugular bulb. *ICA* internal carotid artery, *IJV* internal jugular vein, *IX* glossopharyngeal nerve, *X* vagus nerve, *XI* accessory nerve

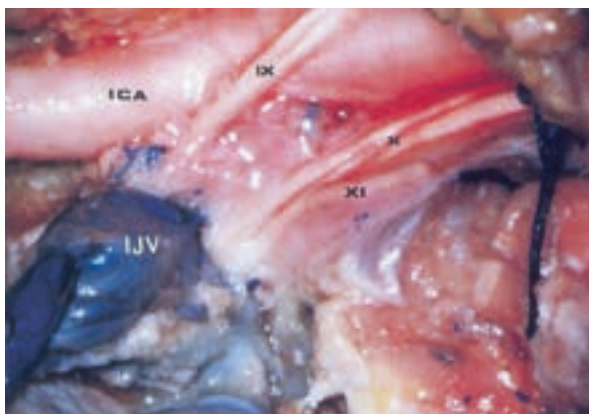
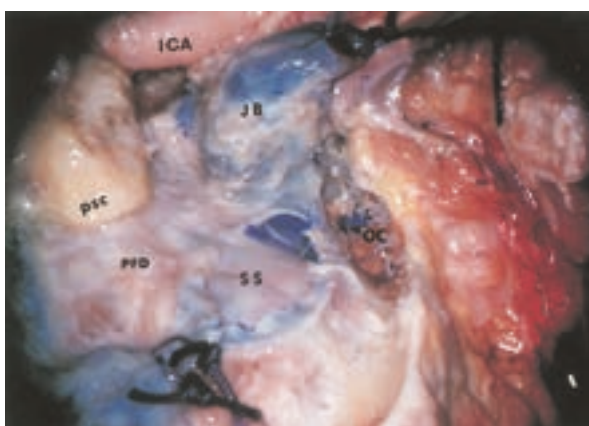


Fig. 8.21 Drilling of the occipital condyle posterior to the jugular bulb. *ICA* internal carotid artery, *PFD* posterior fossa dura, *SS* sigmoid sinus, *JB* jugular bulb, *psc* posterior semicircular canal, *OC* occipital condyle



carefully to prevent it from being damaged. If necessary (as in the case of TJPs), the lateral wall of the sigmoid sinus can be removed (Fig. 8.21). Removal continues down to the level of the jugular bulb. The lateral wall of the jugular bulb is opened. Bleeding usually occurs from the apertures of the inferior petrosal sinus and the condylar

emissary vein. This is controlled by Surgicel packing (Fig. 8.22). If there is limited intradural extension, the dura is opened without injury to the endolymphatic sac (Fig. 8.23). Figures 8.24, 8.25, and 8.26 show the view after the dura of the posterior fossa has been opened. At the end of the procedure, the Eustachian tube (Fig. 8.27) is

Fig. 8.22 The inferior petrosal sinus opens into the medial wall of the jugular bulb and is seen after excision of the bulb. *Co* cochlea, *FN* facial nerve, *ICA* internal carotid artery, *IPS* inferior petrosal sinus, *LSC* lateral semicircular canal, *PFD* posterior fossa dura, *psc* posterior semicircular canal, *IX* glossopharyngeal nerve, *X* vagus nerve, *XI* accessory nerve

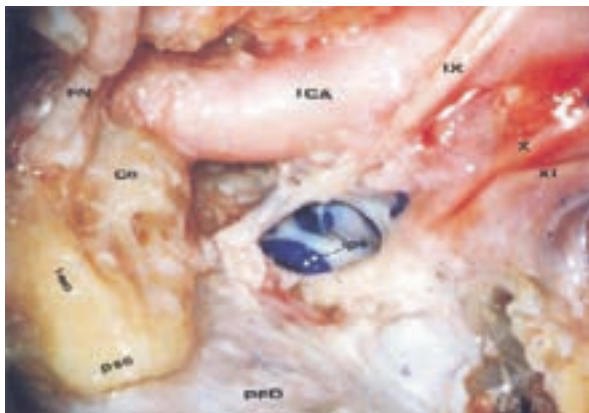

Fig. 8.23 The posterior fossa dura is opened. *Cbl* cerebellum, *Co* cochlea, *ELS* endolymphatic sac, *ICA* internal carotid artery, *IPS* inferior petrosal sinus, *psc* posterior semicircular canal, *IX* glossopharyngeal nerve

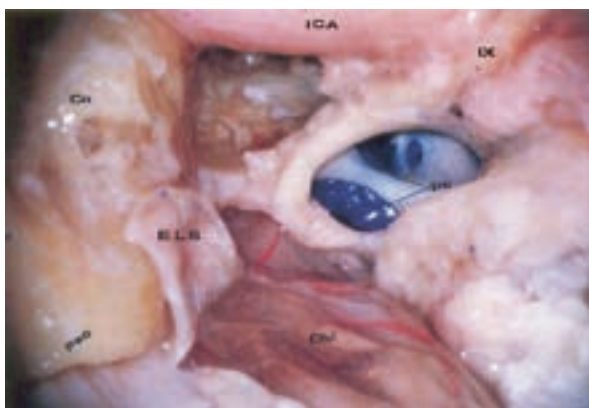


Fig. 8.24 The glossopharyngeal and vagus nerves are well identified in the cerebellomedullary cistern before entering the jugular foramen. *PFD* posterior fossa dura, *psc* posterior semicircular canal, *IX* glossopharyngeal nerve, *X* vagus nerve

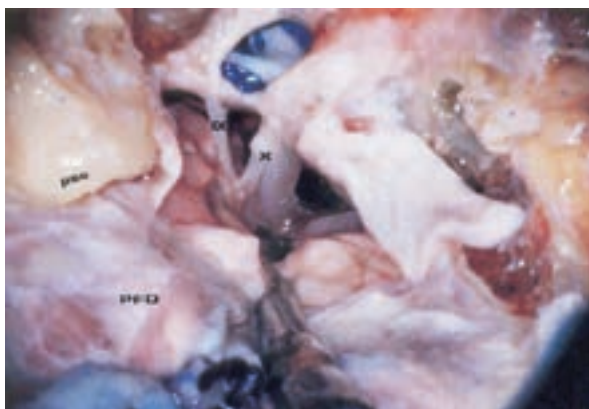


Fig. 8.25 The facial and vestibulocochlear nerves and the anterior inferior cerebellar artery are visible. *AICA* anterior inferior cerebellar artery, *Co* cochlea, *ICA* internal carotid artery, *psc* posterior semicircular canal, *VII* facial nerve, *VIII* vestibulocochlear nerve

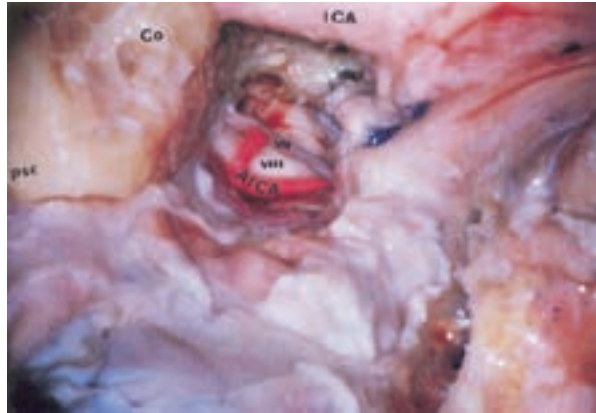


Fig. 8.26 A closer view shows the anterior inferior cerebellar artery passing between the seventh and eighth nerves. *AICA* anterior inferior cerebellar artery, *Co* cochlea, *psc* posterior semicircular canal, *VII* facial nerve, *VIII* vestibulocochlear nerve

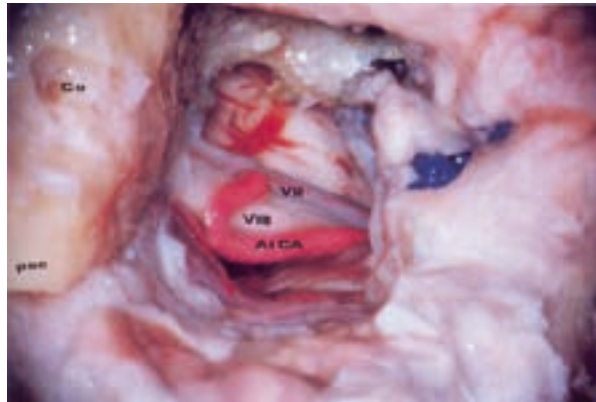
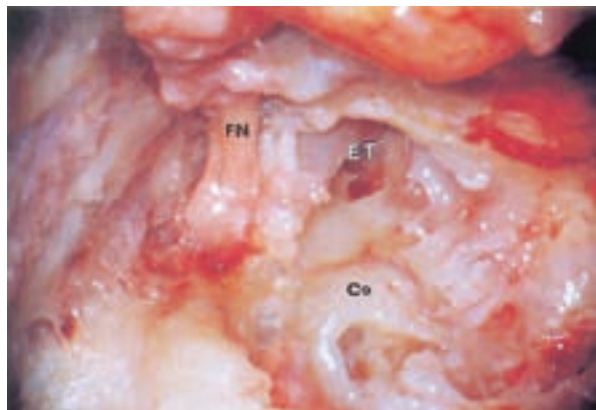


Fig. 8.27 Relationship of the re-routed facial nerve to the cochlea and the Eustachian tube. *Co* cochlea, *ET* Eustachian tube, *FN* facial nerve



closed by a piece of muscle. The dural opening is closed by a muscle plug or with only abdominal fat. We never use a rotated temporalis muscle (as suggested by Fisch) in order to avoid aesthetic problems, but the sternocleidomastoid muscle and the digastric muscle are sutured together, and the temporalis muscle is left in its place.

Extensions of the ITFA Type A Approach

Based on the IFTA approach, various extensions can be added depending upon the extent of the pathology. The standard extension we use is a transcondylar-transstubercular extension for C2–C4 tumors (Fig. 8.28). This allows additional posteroinferior and medial access to the jugular fossa, widening the exposure, thus facilitating venous and neural control. The widened angle also affords better access to the petrous apex, medial to the carotid artery. Very rarely a far lateral is employed with full exposure of the vertebral artery (Fig. 8.29). The use of a translabyrinthine extension is occasionally required for otic capsule involvement. A modified transcochlear approach is uncommonly required to access petrous apex, clival involvement, and infratemporal fossa involvement.

Fig. 8.28 Transcondylar-transstubercular extension improves postero-inferolateral and medial exposure

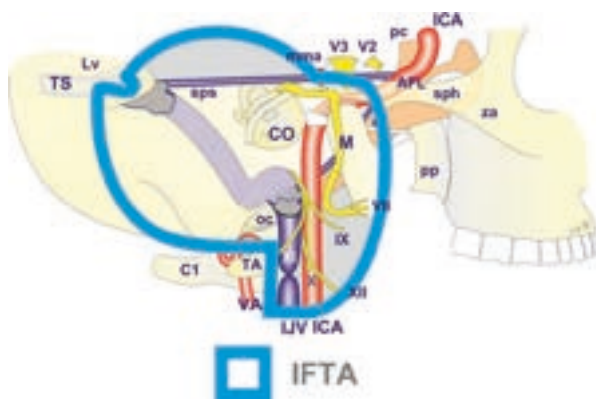
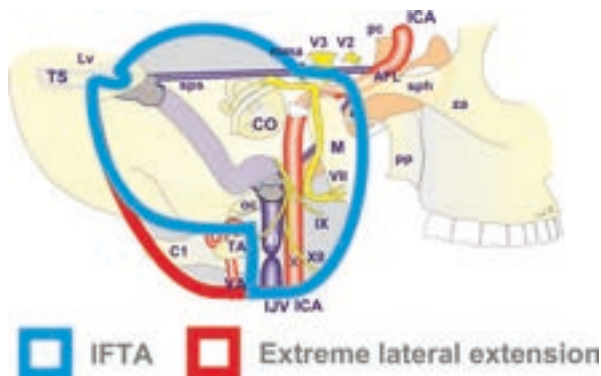


Fig. 8.29 Far-lateral approach further extends postero-inferolateral exposure



Transcondylar-Transtubercular Extension of the ITFA Type A

The classic infratemporal fossa approach type A of Fisch permits only superior and anterior exposure of the jugular bulb and is indicated for class C1 and certain C2 tumors. For larger tumor such as class C2, C3, and C4 tumors involving the lower cranial nerves, a transcondylar-transtubercular extension is required in addition to the classic infratemporal fossa approach type A. This extension facilitates inferomedial access to the jugular bulb above the lateral mass of the atlas and occipital condyle (Figs. 8.30 and 8.31).

Fig. 8.30 Comparison of class IFTA and IFTA with transcondylar-transtubercular extension. *Red line zone:* classic infratemporal fossa approach type A. *Blue line zone:* infratemporal fossa approach type A with transcondylar-transtubercular extension. *CF* carotid foramen, *MT* mastoid tip, *DR* digastric ridge, *JF* jugular foramen

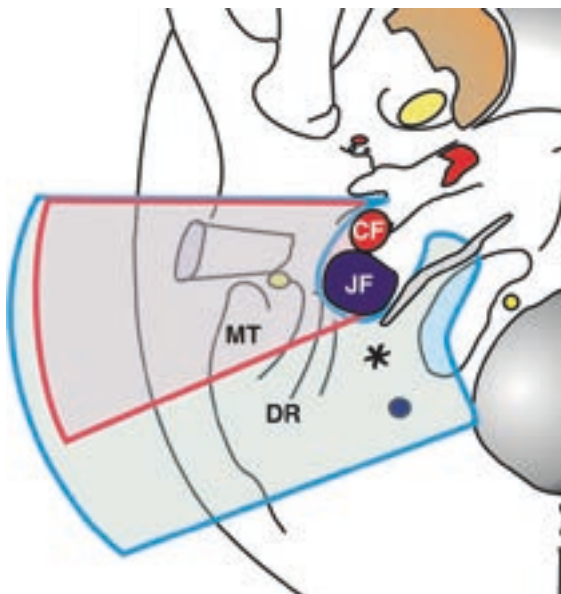
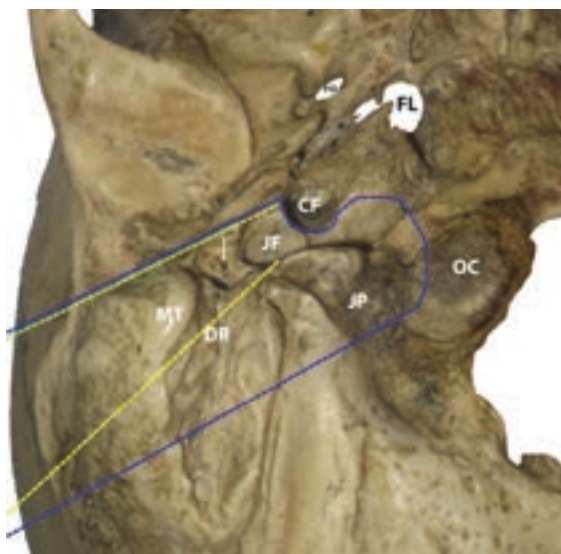


Fig. 8.31 Inferior view of skull base, comparison of classic ITFA by Fisch, and modified ITFA with transcondylar-transtubercular extension. In addition to removal of bone in classic ITFA by Fisch, drilling of the jugular process of the occipital bone and even some of the occipital condyle facilitates control of the area of the jugular bulb. *Yellow dash line:* classic ITFA by Fisch. *Blue dash line:* modified ITFA with transcondylar-transtubercular extension. *FO* foramen ovale, *FL* foramen lacerum, *CF* carotid foramen, *JF* jugular foramen, *JP* jugular process of the occipital bone, *MT* mastoid tip, *DR* digastric ridge, *OC* occipital condyle



Steps of ITFA Type A with Transtuberular-Transcondylar Extension

As described in the previous pages, the ITFA type A approach is performed. The transcondylar-transtuberular approach begins with the identification of the splenius capitis muscles. The posterior fossa dura is uncovered toward the occipital skull base in order to start drilling of the jugular process and occipital condyle. The drilling of the jugular process is commenced followed by the identification and drilling of the occipital condyle superior to the atlanto-occipital joint posteromedial to the jugular bulb (Figs. 8.32 and 8.33). The hypoglossal canal is then identified between the jugular tubercle and occipital condyle above the vertebral artery, if indicated (Figs. 8.34, 8.35, 8.36, 8.37, 8.38, and 8.39).

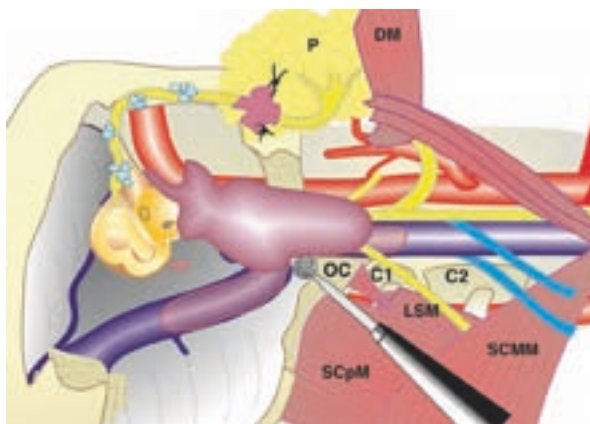


Fig. 8.32 The styloid process is completely removed. In order to fully expose posterior and medial aspects of the tumor, a transcondylar-transtuberular extension is performed. For this, the jugular process and occipital condyle (OC) of the occipital bone are drilled out. C1 atlas, C2 axis, DM posterior belly of the digastric muscle, LSM levator scapulae muscle, P parotid gland, SCMM sternocleidomastoid muscle, SpCM splenius capitis muscle

Fig. 8.33 After removal of the jugular process, the jugular tubercle (JT) and hypoglossal nerve (XII) are identified. C1 atlas, C2 axis, DM posterior belly of the digastric muscle, LSM levator scapulae muscle, OC occipital condyle, P parotid gland, SCMM sternocleidomastoid muscle, SpCM splenius capitis muscle

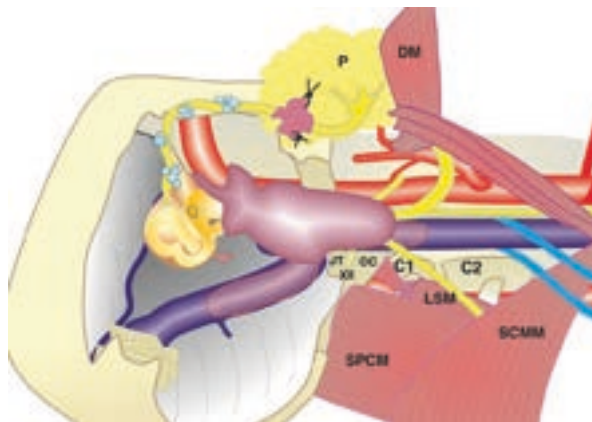


Fig. 8.34 The jugular process and the portion of the occipital condyle have been drilled out. The left occipital condyle is identified below the jugular bulb and posterior to the internal jugular vein. *ICA* internal carotid artery, *P* promontory, *LSC* lateral semicircular canal, *JB* jugular bulb, *IJV* internal jugular vein, *SS* sigmoid sinus. *Occipital condyle

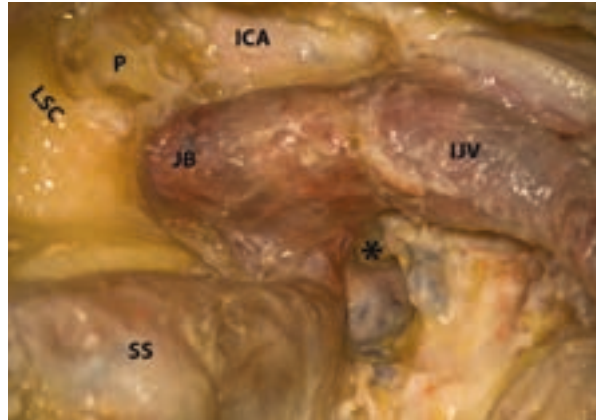


Fig. 8.35 The lateral aspect of the jugular bulb, sigmoid sinus, and internal jugular vein has been removed. On the medial wall of the jugular bulb, the inferior petrosal sinus is identified. The opening of the posterior condylar vein is seen. *ICA* internal carotid artery, *P* promontory, *JB* jugular bulb, *SS* sigmoid sinus. *Occipital condyle

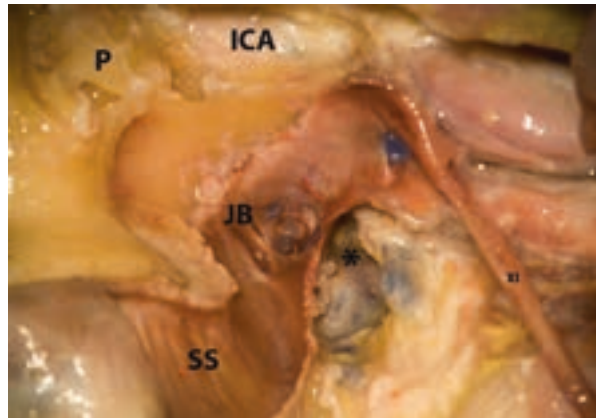


Fig. 8.36 The inferior petrosal sinus and the posterior condylar veins open into the medial wall of the jugular bulb. *IPS* inferior petrosal sinus, *IJV* internal jugular vein, *PCV* posterior condylar vein, *JV* jugular vein. *Occipital condyle

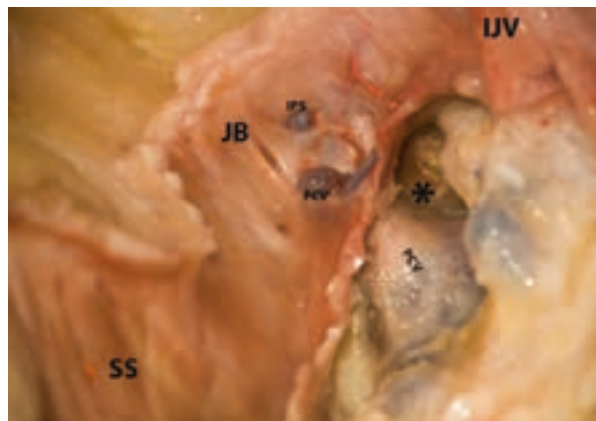


Fig. 8.37 Note the relationship among the sigmoid sinus, jugular bulb, posterior condylar vein, vertebral artery, and lower cranial nerves. *IPS* inferior petrosal sinus, *JB* jugular bulb, *PCV* posterior condylar vein, *JV* jugular vein, *VA* vertebral artery, *TP* transverse process of C1, *C1* the first cervical vertebra, *C2N* the second cervical vertebra, *X* vagus nerve, *XI* spinal accessory nerve. *Occipital condyle

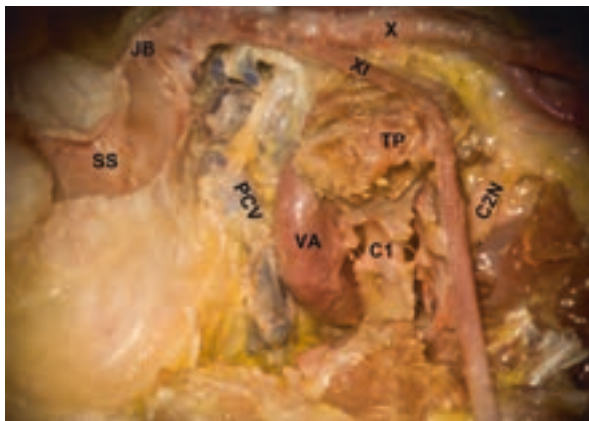

Fig. 8.38 The posterior condylar vein crossing the occipital condyle is noted. *IX* glossopharyngeal nerve, *XI* spinal accessory nerve, *ICA* internal carotid artery, *JB* jugular bulb, *PCV* posterior condylar vein

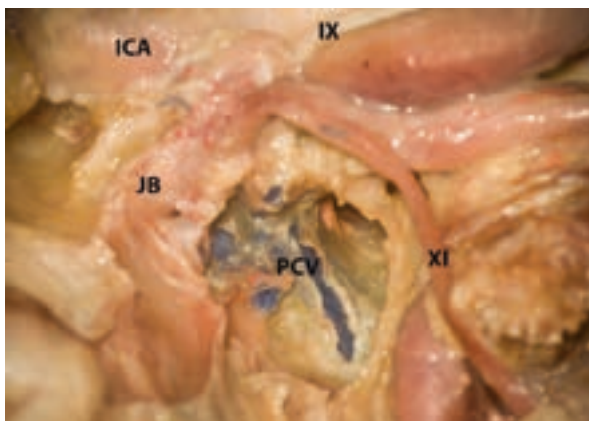
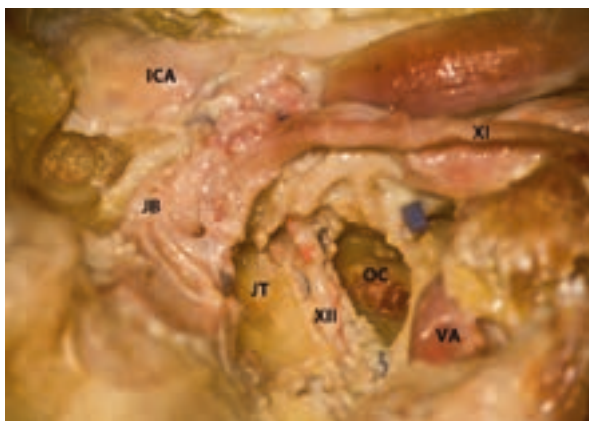

Fig. 8.39 After removal of the posterior condylar vein and further removal of the occipital condyle (OC), the hypoglossal nerve (XII) is noted. *XI* spinal accessory nerve, *ICA* internal carotid artery, *JB* jugular bulb, *JT* jugular tubercle, *VA* vertebral artery



The tumor removal is commenced at this point. The IJV is closed with vascular clips. The IJV is mobilized up to the jugular fossa by mobilizing it away from the spinal accessory nerve. The tumor is peeled away from the dura of the posterior cranial fossa. The infiltrated bone of the fallopian canal and tympanic bone is then drilled out. The tumor is debulked from the jugular bulb area. The infiltrated infralabyrinthine cells are drilled out. The sigmoid sinus is opened to expose the tumor within. The IJV is opened to expose the distal end of the tumor. The inferior petrosal sinus is packed with Surgicel[®]. The tumor is then separated from the lower cranial nerves. The ICA is identified after extensive drilling of the bone of the vertical portion of the carotid canal, and the tumor around is coagulated with bipolar coagulation. The tumor is gently separated from the wall of the ICA. Further drilling of all the suspect bones of infralabyrinthine and apical cells is carried out until complete removal is accomplished. If required, the internal carotid artery is partially mobilized, and the infiltrated clivus is drilled out. The posterior fossa dura is not opened, and the intradural portion of the tumor is left behind to be removed in a second stage. The closure of the Eustachian tube, cavity obliteration, and watertight closure of the subcutaneous and cutaneous tissue are carried out as with the conventional ITFA type A.

Considerations in the Management of Complex TJPs

Complex TJPs are a challenge to even the most experienced skull base team. The following issues need to be taken into consideration while managing such complex cases.

Very large size—As TJPs grow, they extend either into the carotid canal and the petrous apex or into the intradural space through the medial wall of the jugular bulb and thereby involving the LCNs. A large size obviously brings into play the other factors mentioned above that complicate the presentation of TJPs discussed below. Fisch class C3 and C4 tumors are generally considered as large tumors. Of the 245 TJPs treated at our center, we managed 35 patients with tumors considered to be of a large size, of which 27 were Fisch C3, 5 were C4, and 3 were De2. As a rule, ITFA-A is used for C2 tumors, and ITFA-A or ITFA-A combined with ITFA-B can be used for C3/C4 tumors. If the tumor involves the clivus, occipital condyle, or foramen magnum, additional procedures such as MTCA or ELTCA are necessary and were performed at our center.

Large intradural extension (IDE)—Although some authors prefer a single-staged surgery [11], we feel that if an extensive area of dura is involved by tumor, a planned second-stage resection can be considered. We managed a total of 45 patients with IDE: 25 with Fisch Di1, 18 Di2, and 2 Di3. In 14 of them, a staged surgery was performed. The advantage of a staged surgery is that a clear plane of dissection would have been established between the tumor and the brain stem due to the devascularization of the tumor at the first-stage surgery and subsequent shrinkage of the intradural mass (Fig. 8.40a–d). Another consideration is that in tumors involving

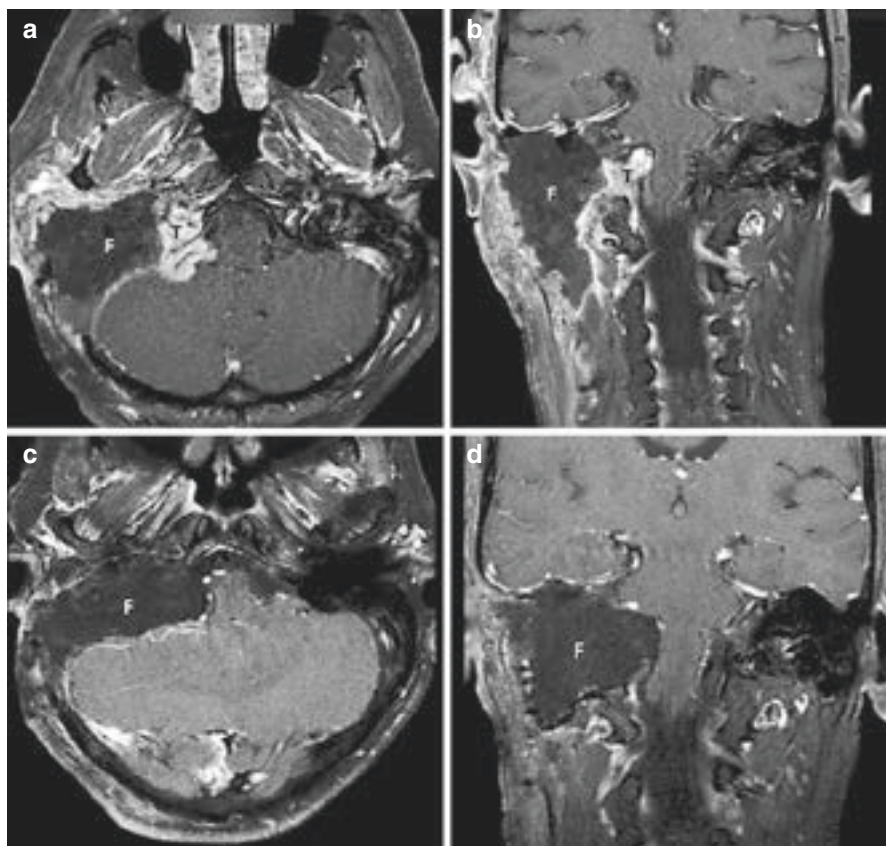


Fig. 8.40 (a, b) MRI, axial, and coronal views after the first-stage surgery. The residual intradural tumor is noted. The surgical defect is filled with abdominal fat. *T* intradural tumor, *f* fat. (c, d) MRI, axial, and coronal views after the second-stage surgery. After the surgery, there is no residual tumor

LCNs, their sacrifice could cause severe aspiration with continuous cough. The resulting increase in intracranial pressure could give rise to CSF leaks [38]. To also prevent any such postoperative CSF leaks, we prefer a staged surgery for tumors with more than 2 cm IDE. At the second stage, the approach is determined by the location and size of the residual tumor and the patient's hearing function. Although the petro-occipital trans-sigmoid approach is preferred in most cases, a MTCA or an ELTCA may also be used.

Extension to the foramen magnum, clivus, or the cavernous sinus—For tumors extending to the foramen magnum and lower clivus, MTCA type D or the ELTCA may be used [5]. In order to prevent tumor recurrence, any part of the clival bone suspected of being infiltrated must be drilled out until healthy bone appears. We had 13 patients: 2 with tumor involvement of the cavernous sinus, 3 of foramen magnum, and 8 of the clivus. In two of them, the tumor involved the cavernous sinus, and they were intentionally left intact to avoid compromising cranial nerves III, IV,

and VI and maintain ocular mobility. After surgery, stereotactic radiotherapy was carried out in both patients. We had three cases involving the foramen magnum, and total removal was difficult to achieve in one of them due to persistent bleeding.

Involvement of the ICA—TJPs frequently involve the ICA due to their close anatomical proximity [39]. When indicated, the tumor must be dissected from the arterial wall. This can be achieved by subperiosteal (or supra-adventitial) dissection of the ICA in the carotid canal (horizontal portion) or subadventitial dissection in the vertical portion [40]. When the artery is completely surrounded by a tumor resulting in severe stenosis on arteriography, manipulation without proper endovascular intervention may give rise to severe bleeding, incomplete removal, or a cerebral vascular accident [41]. Permanent balloon occlusion is performed when the ICA is infiltrated by the tumor and the collateral blood flow is sufficient. But in cases with insufficient collateral blood flow, we routinely use intraluminal stenting (Figs. 8.41a–d and 8.42). Stenting of the cervical and petrous segments of ICA was introduced as a preoperative management protocol by the Gruppo Otologico in the clinical and surgical management of complex HNPs since the early 2003 as a method to avoid preoperative closure of the ICA or high-risk bypass procedures and to protect and preserve integrity of the artery during surgery, mainly in cases in which the collateral flow through the circle of Willis is deemed insufficient [42–44]. 21 preoperative ICA stenting procedures were performed at our center on 19 patients. Stenting of the ICA allows reinforcement of the artery, reducing the risk of intraoperative injury of its wall while performing a more aggressive carotid dissection in the subadventitial plane. The presence of the stent allows the safe mobilization of the artery if necessary. This new technique can allow reappraisal of selected cases previously suited only for subtotal resection. To the best of our knowledge, the literature contains only one case of stenting of the intratemporal segment of the ICA for the management of TJPs [11].

A single ICA on the lesion side—As mentioned above, management of the ICA is essential for total tumor removal. For a case with a single carotid artery on the lesion side, possible management options are “wait and scan,” partial resection followed by radiotherapy, or total removal subsequent to the preoperative reinforcement with stents [43]. In a patient with a single carotid artery on the lesion side, bypass surgery can cause severe cerebral ischemic damage. Therefore, the stent insertion may be the best option. We have so far treated two patients with a single ICA without any adverse consequences.

Vertebral artery involvement—Although involvement of the VA by TJPs is extremely uncommon, with a total of 11 cases reported worldwide, of which 8 cases belong to our series, it represents the pinnacle of difficulty in management of TJPs. 7/8 patients underwent surgery and the results are summarized. In two patients, preoperative occlusion was performed. In one of our articles [1], we have presented the radiological and surgical findings of VA involvement by TJPs to emphasize the importance of VA assessment and propose the addition of the “V” category to the existing Fisch classification. Angiography of the vertebrobasilar system should always be included in the assessment of TJPs planned for surgery. This is to detect anastomotic connections between the external carotid and the VA that

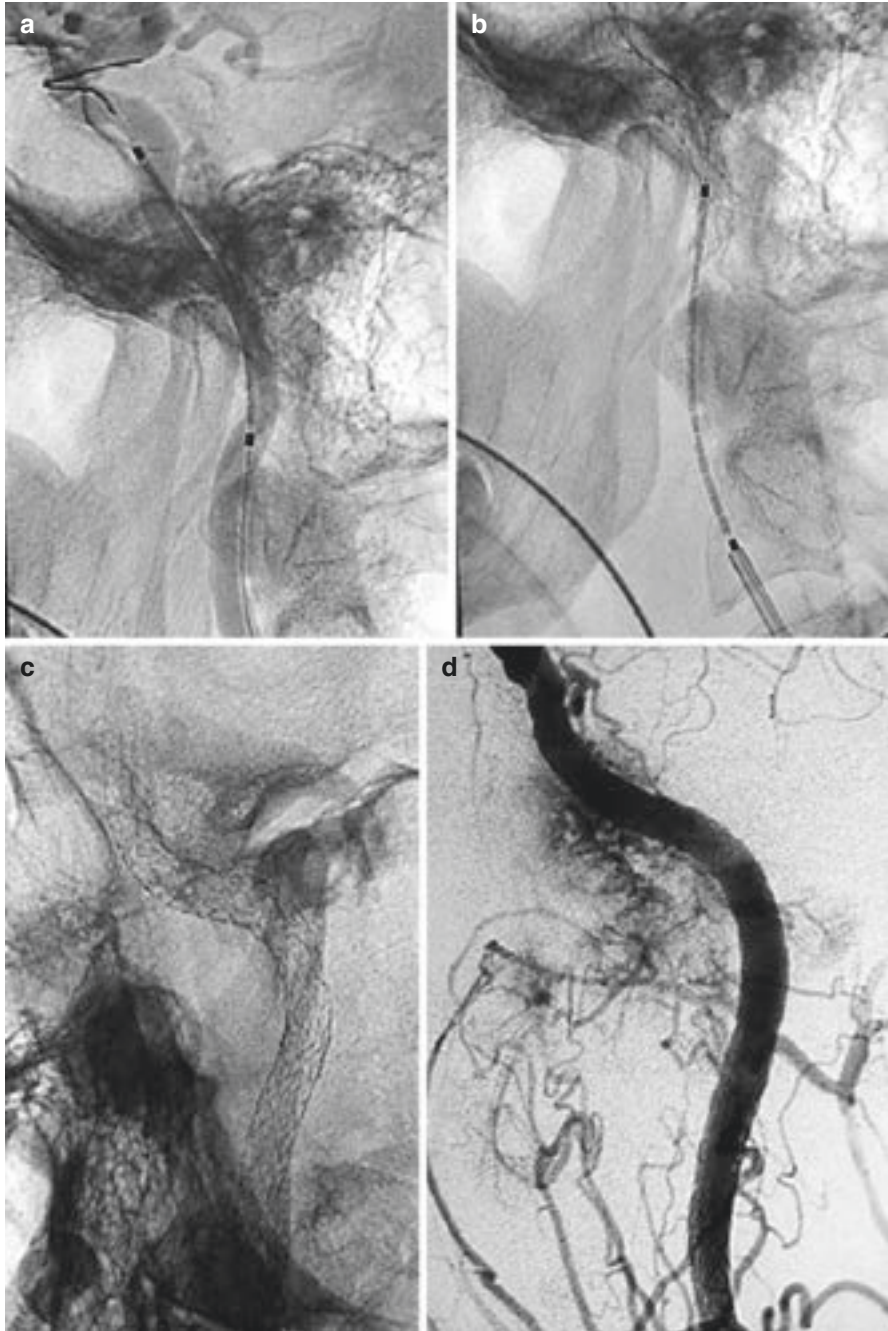



Fig. 8.41 (a, b) Insertion of the stents in the petrous and cervical portions of the internal carotid artery (ICA). (c) Digital x-ray in oblique projection showing the stents fully deployed in the petrous and cervical segments of the ICA. (d) Digital subtraction angiography of the ICA after stenting showing resolution of the stenosis

Fig. 8.42 The view of the internal carotid artery. Tumor removal has been completed. Dissection has been carried out down to the stent in an almost bloodless field



are potentially dangerous during embolization, such as between branches of the ascending pharyngeal, deep cervical, ascending cervical, and occipital arteries with the VA [45], as well as to adequately assess direct involvement of the VA. For the surgical strategy, involvement of the V3 segment requires the addition of an extreme lateral extension to the standard ITFA, in order to ensure its adequate exposure. The V4 segment involvement is inevitably accompanied by a large IDE. In such cases, we prefer a two-stage surgery (Fig. 8.43a–f).

Dominant or unilateral sigmoid sinus on the lesion side—The SS obliteration and the jugular vein often need to be ligated during resection of TJPs. However, ligation SS of the dominant or the presence of unilateral SS on the lesion side may cause intracranial hypertension and venous congestion leading to swelling of the brain [5]. Therefore, preoperative evaluation of venous drainage of the brain is essential, especially of the ipsilateral mastoid emissary vein or the condylar vein. If their diameters are larger than normal, they should be preserved during surgery. In cases where the collateral venous drainage cannot be preserved or when the patient has no sufficient collateral venous drainage, a more conservative treatment plan such as partial resection with preservation of the SS, gamma knife surgery, or a “wait and scan” approach is recommended.

Bilateral or multiple head and neck paragangliomas—In the management of bilateral TJPs, the possibility of bilateral deficits of important LCNs looms large, and hence neural preservation is very important to achieve a good quality of life for the patient postoperatively. We had 11 patients with multiple HNPs. According to our management protocol, in patients with LCN deficits on the side of the larger tumor, it is removed first, and then the smaller tumor is either followed up or irradiated. On the contrary, if the patients have LCN deficits on the side of the smaller tumor, it is removed first, and then the larger tumor is followed up with MRI. During follow-up, if the larger tumor shows evidence of growth, it may be partially removed with the preservation of LCN function or irradiated. In patients with no LCN deficit, the “wait and scan” approach is first applied. However, if the tumor shows growth, radiotherapy or subtotal removal

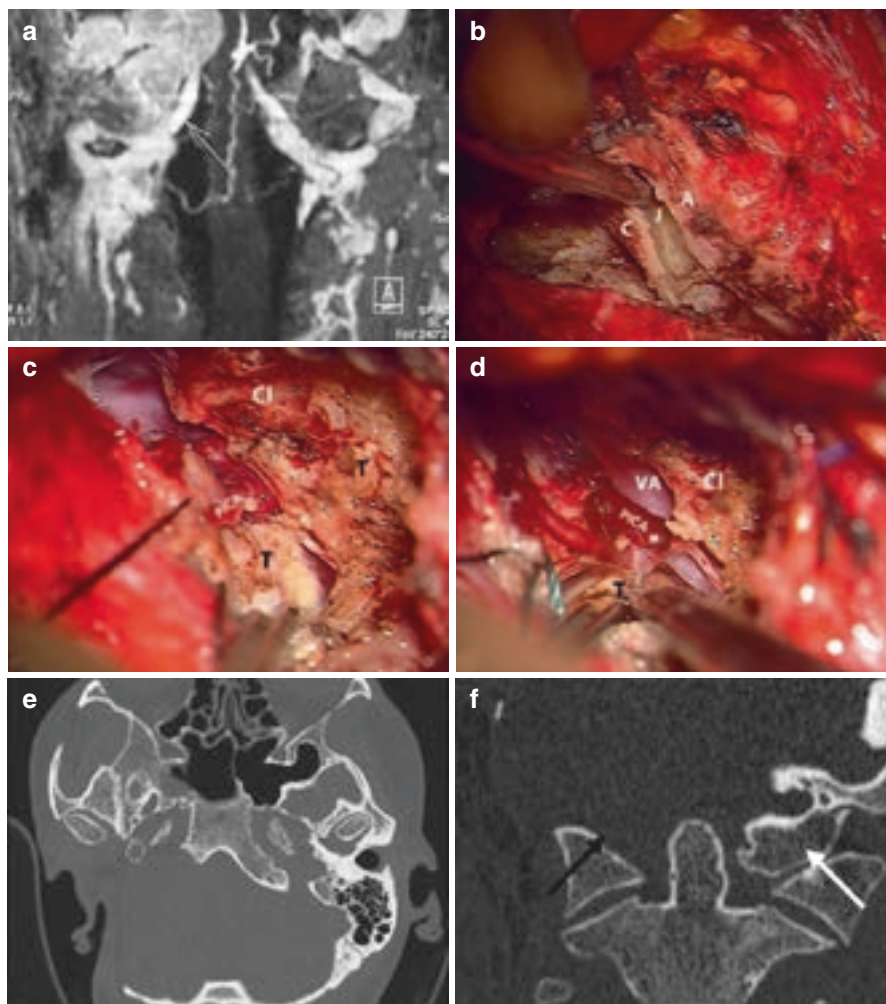


Fig. 8.43 (a) A class C4Di2Vi tumor. MRI coronal image showing the tumor attached to the VA. (b–f) Surgical sequences of extreme lateral transcondylar approach. (b) The transverse process of the atlas (A) is drilled out, and the atlanto-occipital joint (J) is removed. C condyle. (c) The tumor (T) is attached to the vertebral and posterior inferior cerebellar arteries infiltrating the clival (Cl) bone, which is partially drilled out. (d) The tumor is separated from the PICA. (e) CT scan. Axial view showing the stent in the ICA and the extent of bone removal. (f) CT scan coronal view showing absence of the surgically removed occipital condyle (*black arrow*) compared to non-operated side (*white arrow*)

of the tumor with LCN preservation is performed first. Subsequently, if the tumor continues to grow despite radiotherapy or surgical removal, the other remaining modalities can be applied.

Recurrence after previous surgery, radiotherapy, or stereotactic radiosurgery—Any revision surgery is a challenge as there are no normal tissue planes and surgical

landmarks. Previous surgery or radiation increases the risk of CSF leak and damage to the LCNs and FN [5, 41]. The carotid canal is the most common site for recurrence in TJPs, and previous dissection increases the risk of injury to the ICA. In such cases, the preoperative management of the ICA by permanent balloon occlusion or stenting is especially important. An ITFA-A with FN rerouting should be performed in all cases with the appropriate extension and extensive bone removal. In our opinion, there is no place for a conservative approach for the FN and external auditory canal in revision surgery. In our present series, 13 cases had undergone previous treatment.

Hints

- Routinely drilling out the jugular process and jugular tubercle improves access in all TJPs.
- Care is taken to fully uncover the geniculate ganglion. Sharp bone left at this level might injure the anteriorly transposed nerve.
- During anterior rerouting of the FN, a Beaver knife is used to cut the sharp attachments of the mastoid segment of the FN.
- A soft tissue cuff is left around the nerve at the level of the stylomastoid foramen. This tissue affords protection for the nerve during transposition. It also helps to maintain vascularity of the nerve.
- Removing the large intradural part of the tumor would necessitate a larger dural opening and therefore a higher risk of postoperative cerebrospinal fluid leakage. In such cases, a second-stage operation is needed to remove the intradural component of the tumor.
- There is no need to displace the vertebral artery during drilling of the occipital condyle. This procedure permits better control of the posteroinferior spread of the tumor.
- Drilling out of the one-third lateral part of the occipital condyle permits complete visualization of inferior aspect of the jugular bulb.
- In some cases, the occipital condyle is infiltrated by the tumor. The partial removal of the occipital condyle improves a postero-inferolateral and medial exposure reducing the possibility of recurrences.
- TJPs usually infiltrate the jugular bulb and insinuate into the openings of the inferior petrosal sinus. Such fingerlike tumor projections should be removed, and bleeding is controlled with Surgicel packing. However, overzealous packing should be avoided as it might cause excessive swelling with resultant paralysis of the intimately related lower cranial nerves due to compression.
- Preservation of the medial wall of the jugular bulb is necessary to save lower cranial nerve function if there is no tumor infiltration.
- The cochlea may be involved by TJP in spite of normal preoperative hearing. In these cases, total tumor removal necessitates its removal.

- In cases of class C3–C4 tumors with risk of carotid blowout or previously irradiated cases, we can utilize definitive balloon occlusion instead of a preoperative stenting of the ICA.
- Subtotal removal is indicated in tumor that extends to the cavernous sinus to avoid neurologic deficits. In these cases, the patient is sent for radiotherapy if growth is demonstrated at follow-up.
- Preservation of the branches of the external carotid artery would allow for the possibility of tumor embolization prior to any planned second-stage surgery.

Pitfalls

- Before anterior transposition is performed, the FN has to be liberated in the parotid gland. This provides an extra length of free nerve and prevents it from being stretched during the transposition.
- Direct suction over the FN is avoided. A Brackmann suction tip is used instead. Cottonoids can also be used to avoid direct trauma from the suction tip.
- Care should be taken while applying the Fisch infratemporal retractor so as not to injure the FN. We do not use the Fisch retractor anymore, but a self-retaining retractor.
- While removing the base of the styloid process, the utmost care has to be taken not to injure the internal carotid artery lying immediately deep to it.
- The internal carotid artery is surrounded by a dense fibroperiosteal layer at its entrance in the skull base. The glossopharyngeal nerve lies deep to this layer and is slightly adherent to its undersurface. Care has to be taken not to injure the nerve while dissecting tumors at this level. In large TJPs, however, the nerve has been usually infiltrated, and it is therefore sacrificed.
- Care is taken not to injure the hypoglossal nerve which traverses the condyle at a more anterior level. In about 50% of cases, the accessory nerve passes anterolateral to the internal jugular vein in the neck. After ligating the vein, care is taken to not injure the nerve during elevation of the vein. We currently preserve the medial wall of the internal jugular vein and jugular bulb if not infiltrated, which afford protection for the closely related lower cranial nerves.
- With paragangliomas, all cancellous bone should be removed if suspected. The Haversian system of this bone is usually invaded by the tumor and is a frequent cause for recurrence. Drilling should continue until sound bone is reached. This is especially important in the area lying between the basal turn of the cochlea and the internal carotid artery. The bone from the petrous apex lying medial to the internal carotid artery should also be drilled if suspected.
- There is no need to use the transposition of the temporalis muscle for obliteration of dead space.
- Anterior displacement of the mandible is not required.

Conclusion

An infratemporal fossa approach type A with transcondylar-transtubercular extension is required for C2–C4 tumors. 70% of patients recover to House-Brackmann grade I or II following anterior rerouting of the FN. Hence, permanent anterior rerouting of the FN offers definite advantages in C2–C4 TJPs, and a mild FN palsy is a small price to pay to achieve total tumor clearance in large tumors. An unprotected ICA should never be placed at risk during dissection. This risk is avoided with intraluminal stent of the ICA. Safe subadventitial dissection of the ICA involvement is possible with the use of an intra-arterial stent. Staged procedures are mandatory when the intradural extension is larger than 2 cm. Lower cranial nerve palsies are common after paraganglioma surgery. Young patients compensate well, but the elderly can experience significant morbidity. The recurrence rates are about 5–10% despite aggressive surgery even in highly experienced skull base units.

Careful consideration of the complicating factors and thorough preoperative evaluation and intervention can decrease surgical morbidity in TJPs with a high probability of gross total removal. The application of the abovementioned advanced management techniques will definitely improve prognostic results of this subset of tumors.

Representative Case 1 with Detailed Description and Illustration of Surgical Steps of ITFA, Type A

A 33-year-old lady presented with dysphonia and left shoulder weakness. A year back, she was indicated for surgery at another center. During preoperative embolization, she suffered a cerebrovascular accident due to connection between an unidentified branch of the ECA and the vertebral artery. On otoscopy, a retrotympanic reddish mass was noted (Fig. 8.44). Audiogram showed normal hearing. Cranial nerve examination revealed a normal facial nerve function but complete palsy of the IX and X cranial nerves with weakness of the XI and XII cranial nerves. CT revealed tumor in the jugular fossa with infiltration of the bone surrounding the IAC extending toward the genu (Fig. 8.45a). There was no tumor surrounding the horizontal portion of the ICA (Fig. 8.45b). MRI showing tumor extending into the hypoglossal canal. MRI showed confirmed the diagnosis of a C2De1 TJP (Fig. 8.46).

A single-stage IFTA with preoperative embolization was planned. A wide postauricular incision is made with extension down to the neck (Fig. 8.47). The postauricular flap is raised superficial to the superficial layer of the temporalis fascia, in a subcuticular plane (Fig. 8.48). This becomes more difficult toward the mastoid tip, and a subcutaneous fat dissection ensures adequate thickness. This plane of dissection allows the use of the temporoparietal fascia (superficial layer of the temporalis fascia), which can be used as a vascularized pedicled flap in reconstruction. The standard incision is carried a little deeper, however, with preservation of the temporalis muscle fascia and periosteum over the mastoid tip. This layer is maintained into the neck superficial to the superficial layer of the deep cervical fascia over the sternocleidomastoid muscle. This important step preserves a continuous substantial layer to ensure watertight closure. The canal is then transected lateral to

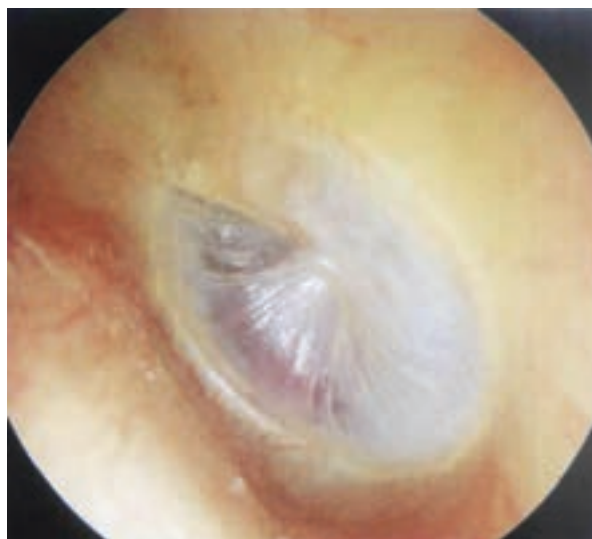
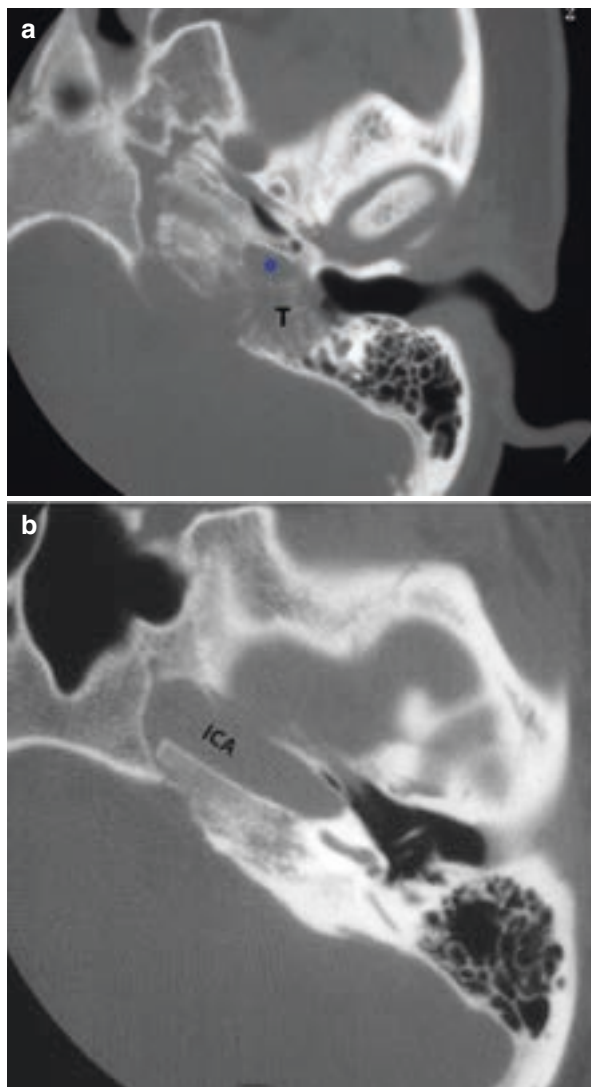


Fig. 8.44 Note the reddish retrotympanic mass in the anteroinferior portion of the tympanic membrane

Fig. 8.45 (a) Asterisk: IAC, *T* tumor. (b) The horizontal segment of the internal carotid artery appears free of tumor. *ICA* internal carotid artery



the bony cartilaginous junction (Fig. 8.49). This allows rapid identification of the cartilage and thus the correct plane of dissection, in addition to providing robust skin with which to form the blind sac closure (Fig. 8.50). An anteriorly based periosteal flap is classically used to reinforce this closure, sutured medially to the remnant cartilage of the EAC. Alternatively, the anterior cartilage can be preserved which then provides an ideal material with which to reinforce the blind sac closure (Figs. 8.51 and 8.52).

The neck dissection is commenced. An incision in the superficial layer of deep cervical fascia is made along the anterior border of the SCMM, with identification

Fig. 8.46 Coronal T1 contrast enhanced MRI showing tumor extending into the hypoglossal canal

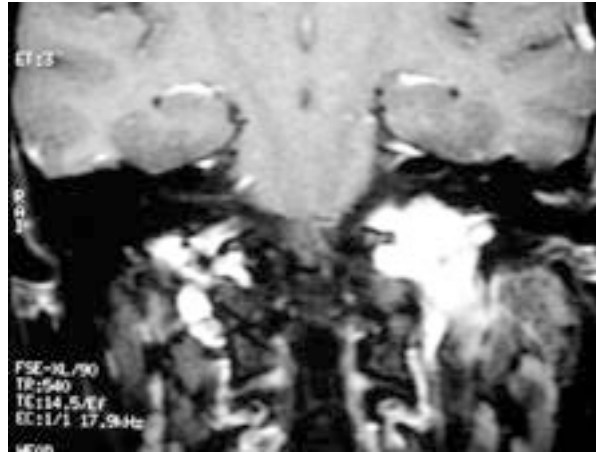


Fig. 8.47 Cranio-temporo-cervical incision

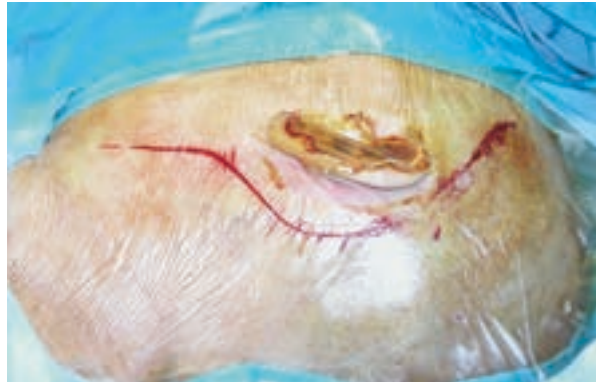


Fig. 8.48 The flap is raised superficial to the superficial layer of the temporalis fascia. EAC external auditory canal

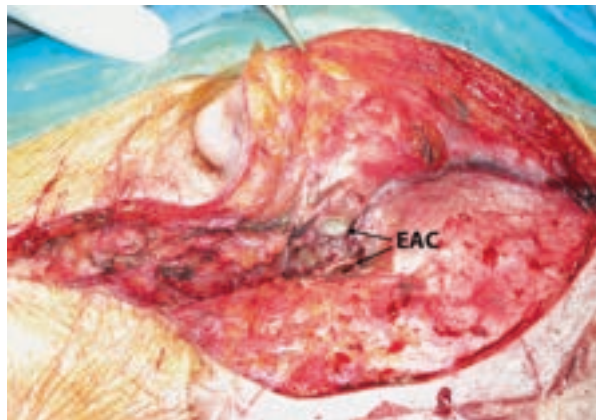


Fig. 8.49 EAC is transected just lateral to the bony cartilaginous junction. *EAC* external auditory canal

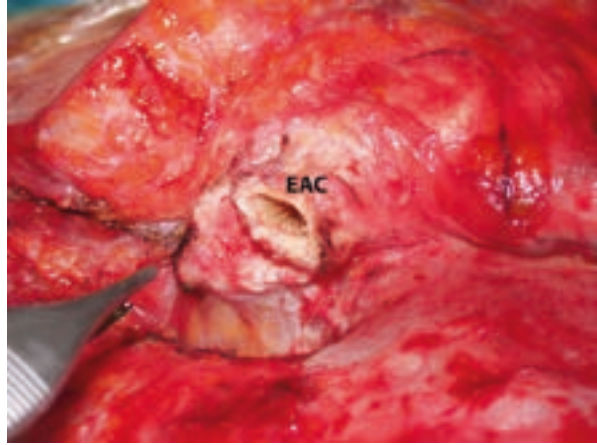

Fig. 8.50 Skin is everted and closed with sutures

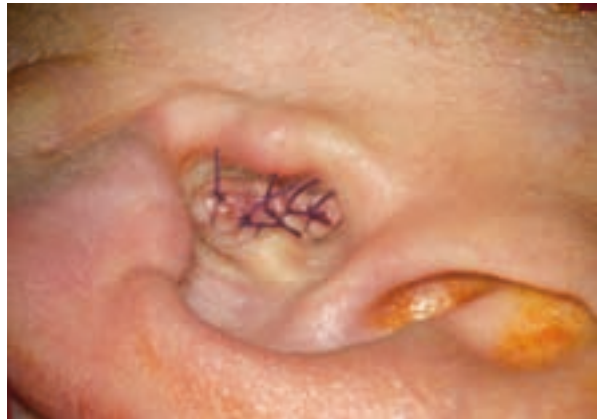

Fig. 8.51 Note that the inferior angle of cartilage represents the “tragal pointer.” *C* cartilage, *EAC* everted external auditory canal

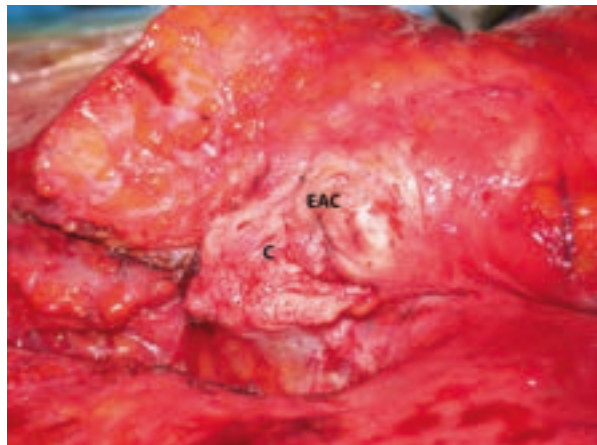


Fig. 8.52 The cartilage (C) is then folded and sutured in place

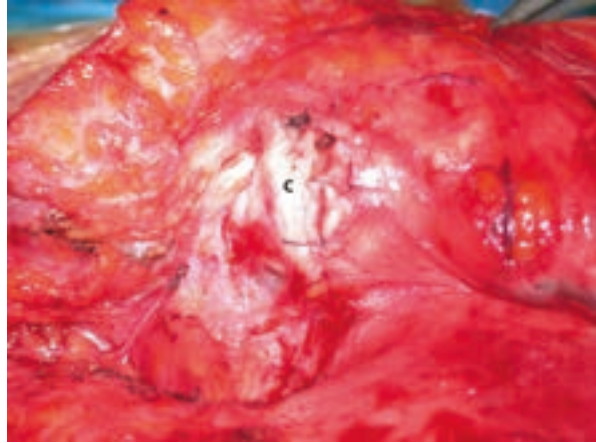
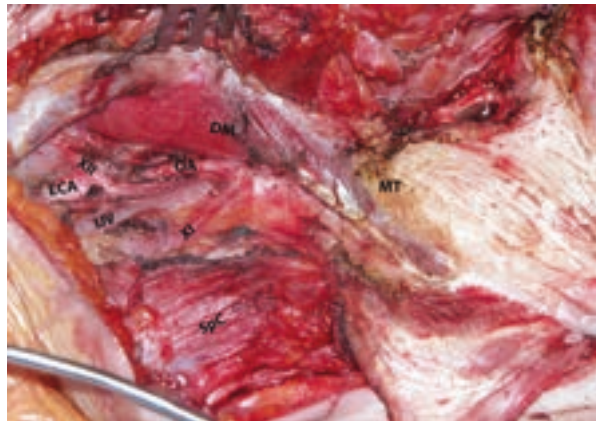


Fig. 8.53 The SCMM has been dissected from the mastoid tip and sutured to the skin edge. The digastric muscle can now be seen inserting into the digastric groove, medial to the mastoid tip. *ECA* external carotid artery, *DM* digastric muscle, *SpCM* splenius capitis muscle, *MT* mastoid tip, *OA* occipital artery, *IJV* internal jugular vein, *XI* spinal accessory nerve, *XII* hypoglossal nerve

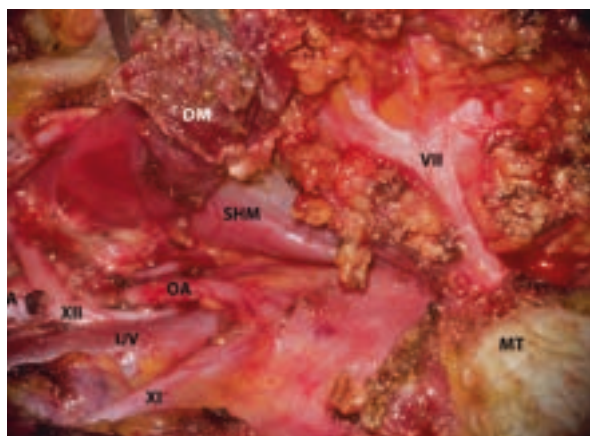


of the digastric muscle, and the neurovascular bundle in the neck (Fig. 8.53). A T-shaped incision is made in the musculofascial layer with a supplementary rectangular-shaped flap created superior to the bony canal to assist in watertight closure. This is designed due to tissue loss as a result of the blind sac closure. Performing the blind sac closure at this stage also assists in anterior access. The extratemporal FN is then identified and exposed at the bifurcation. The exit at the stylomastoid foramen is closely related to the digastric muscle. It is also 6–8 mm anteromedial to the inferior aspect of the tympanomastoid suture line (Fig. 8.54). With the transection of the EAC and anterior retraction of the auricle, the facial nerve appears to be in a more superficial plane than when identifying the nerve via a preauricular incision. Once the facial nerve has been definitively identified, the posterior belly of the digastric muscle is cut using a monopolar diathermy. The transected muscle is retracted anteriorly, further enhancing exposure (Fig. 8.55). Medial to this are the muscles attached to the styloid process beginning with the stylohyoid. Ligation of the facial vein is required to adequately access the carotid

Fig. 8.54 The FN is identified at its exit from the stylomastoid foramen. *EAC* external auditory canal, *DM* digastric muscle, *VII* facial nerve, *MT* mastoid tip

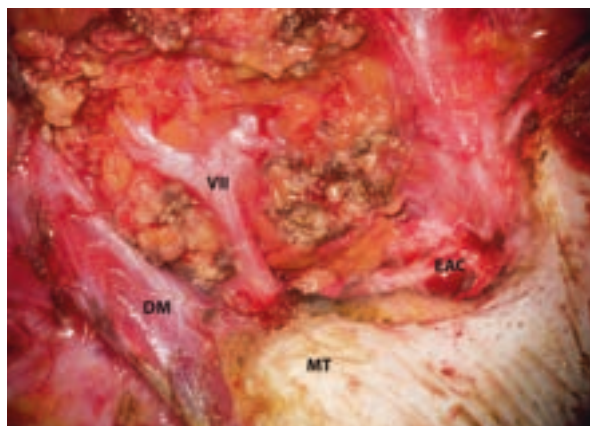

Fig. 8.55 The digastric muscle has been detached with monopolar diathermy. *MT* mastoid tip, *VII* facial nerve, *DM* posterior belly of digastric muscle, *OA* occipital artery, *IJV* internal jugular vein, *XI* spinal accessory nerve, *XII* hypoglossal nerve, *SHM* stylohyoid muscle, *ECA* external carotid artery



sheath. The occipital artery is then identified and ligated. The lateral process of C1 is palpated as a landmark to identify the internal jugular vein and the point at which the XI passes laterally to it in 80–85% of cases. The vagus, spinal accessory, and hypoglossal nerves and the ICA, ECA, and occipital artery are identified and vascular loops passed around the IJV and the ICA (Fig. 8.56). A level II neck dissection is performed in order to sample the lymph nodes for the possibility of metastatic disease.

A wide mastoidectomy is then performed, with care to remove all skin of the EAC. The posterior canal wall, tympanic membrane, malleus, and incus are removed. Care is taken not to leave any bit of squamous material behind (Fig. 8.57). The superstructure of the stapes is then removed using neurosurgical scissors (Fig. 8.58). The crura of the stapes are transected to avoid trauma to the inner ear while dissecting the FN during anterior rerouting. This is essential to avoid sensori-neural hearing loss during anterior rerouting of the FN due to footplate displacement.

Fig. 8.56 The major neurovasculature in the upper neck is identified. *OA* occipital artery, *X* vagus nerve, *XI* spinal accessory nerve, *XII* hypoglossal nerve, *ECA* external carotid artery, *ICA* internal carotid artery, *IJV* internal jugular vein

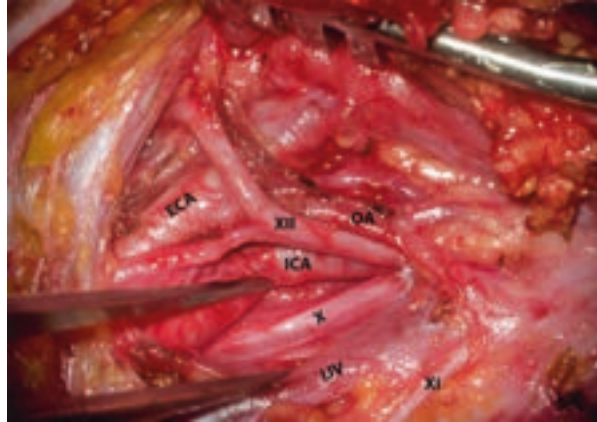
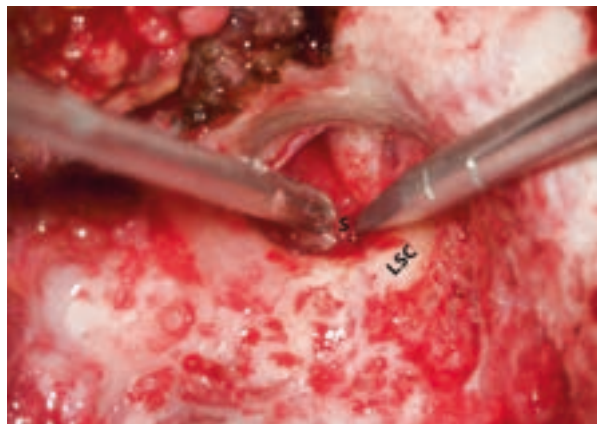


Fig. 8.57 Wide canal wall down mastoidectomy is performed. *T* tumor, *P* promontory, *LSC* lateral semicircular canal

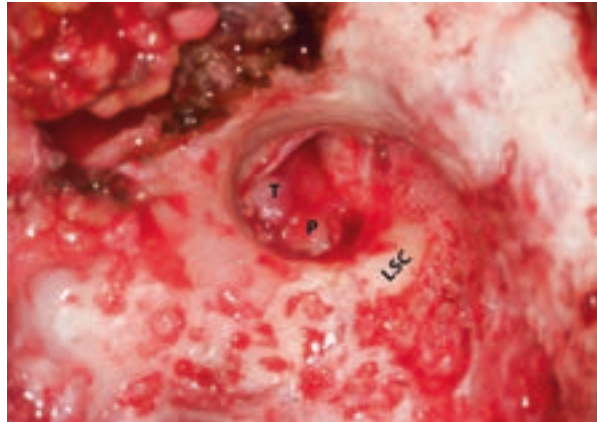

Fig. 8.58 The superstructure of the stapes is removed. *S* stapes, *LSC* lateral semicircular canal



In order to ensure a clear and bloodless field during FN rerouting, the middle ear component of the tumor is always debulked and packed with Surgicel if necessary (Fig. 8.59). This is the only component of tumor that is dissected prior to wide exposure of all margins. The vertical segment of the FN is skeletonized (Fig. 8.60). This is facilitated by drilling the retrofacial air cells and the tympanic bone anterior to the FN. The FN is completely exposed in the fallopian canal bed (Fig. 8.61).

The FN is then decompressed and displaced anteriorly. It is carefully separated from the fallopian canal with Beaver knife (Fig. 8.62). The nerve is allocated a new groove drilled into the anterosuperior wall of the external auditory canal and secured with fibrin glue (Fig. 8.63). Another groove for the terminal portion is created in the parotid gland. Displacement of the FN represents the key point of the surgery because it allows unobstructed control of the jugular fossa and the vertical carotid canal. The most important steps to perform a good anterior rerouting include complete bony decompression of the geniculate ganglion area and sharp dissection of

Fig. 8.59 The middle ear component of the tumor is debulked first

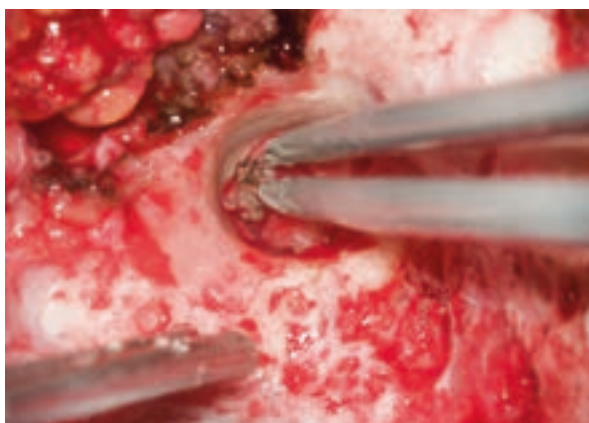


Fig. 8.60 Drill parallel to FN (arrows). Add arrow. *MDP* middle cranial fossa dural plate, *T* tumor

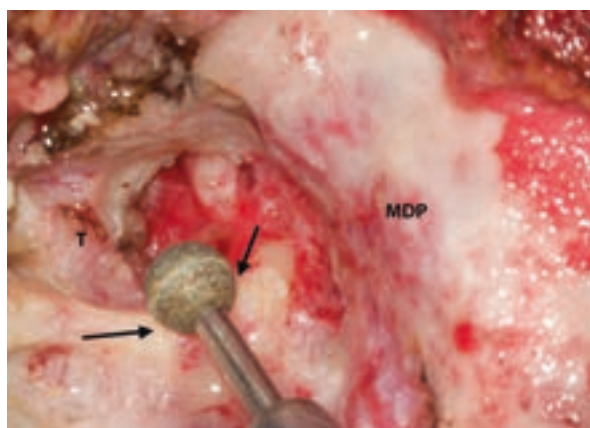


Fig. 8.61 Note the extensive infiltration of the tympanic bone (TB) by tumor. *MCF* middle cranial fossa, *T* tumor, *LSC* lateral semicircular canal, *P* promontory

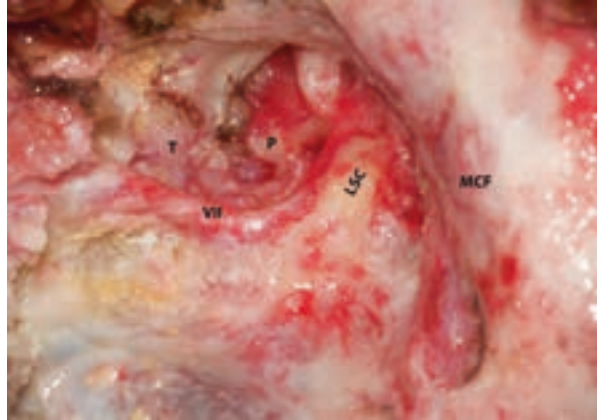

Fig. 8.62 The dense connective tissue at the level of styloid mastoid foramen is freed and the nerve freed from the canal using a Beaver knife. *LSC* lateral semicircular canal, *MCF* middle cranial fossa, *SpCM* splenius capitis muscle, *SS* sigmoid sinus, *VII* facial nerve, *SP* styloid process

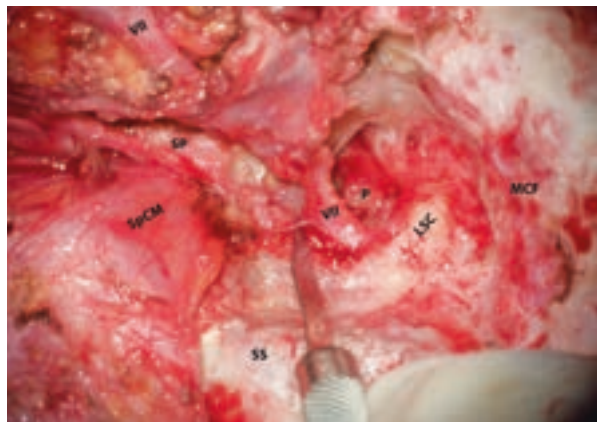
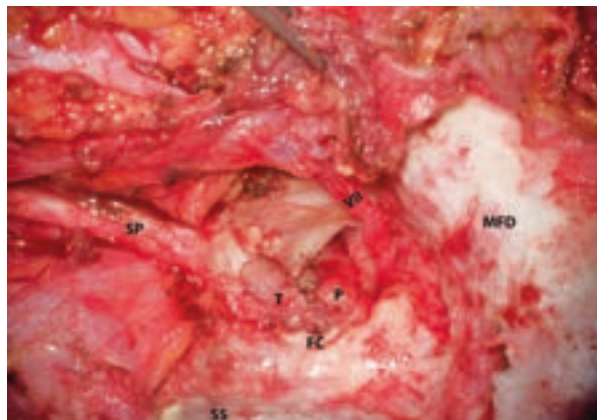


Fig. 8.63 Anterior rerouting is complete. *MFD* middle fossa dura, *SP* styloid process, *SS* sigmoid sinus, *VII* facial nerve, *T* tumor, *FC* fallopian canal, *P* promontory



the nerve from the fallopian canal. An important step in the dissection of the upper neck is the removal of the styloid process and the muscles attached to it (Fig. 8.64). The muscle attachments are detached and the styloid process transected, mindful of the medially placed ICA. The bone posterior to the internal jugular vein is drilled out followed by drilling of the occipital condyle (Fig. 8.65).

Complete removal of the anterior wall of the EAC is rarely required for C1 and C2 tumors, avoiding the use of any retractors. When required, retraction without dislocation of the temporomandibular joint (TMJ) is performed using a standard self-retaining retractor (Fig. 8.66). In rare cases the head of the mandible is mobilized, which is facilitated by the opening of the TMJ and removal of the interarticular disk. The Fisch infratemporal fossa retractor is then placed. Drilling is continued by removing the bone posteroinferiorly which represents the bone of the jugular tubercle of the occipital bone and the posteromedial third of the occipital condyle (Fig. 8.67). Drilling around the occipital condyle, the posterior condylar emissary vein is identified posteriorly. This is controlled with bipolar and/or Surgicel packing.

Fig. 8.64 The styloid process is further detached from the soft tissue with the monopolar diathermy. *VII* facial nerve, *TB* temporal bone, *SP* styloid process, *SpCM* splenius capitis muscle, *SHM* stylohyoid muscle, *IJV* internal jugular vein, *XI* spinal accessory nerve

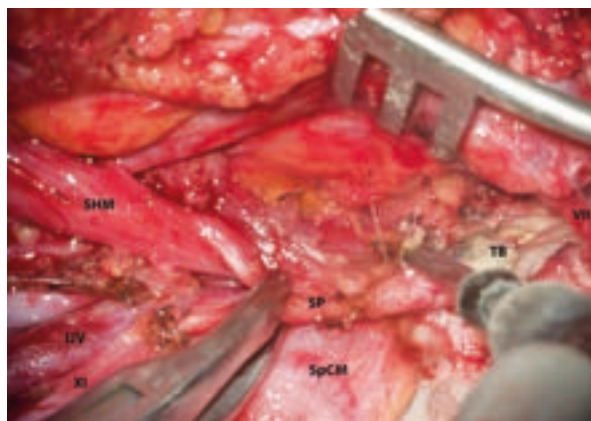


Fig. 8.65 Direction of bone removal is indicated by blue arrows. *P* promontory, *MFP* middle fossa plate, *SS* sigmoid sinus, *VII* facial nerve, *OC* occipital condyle

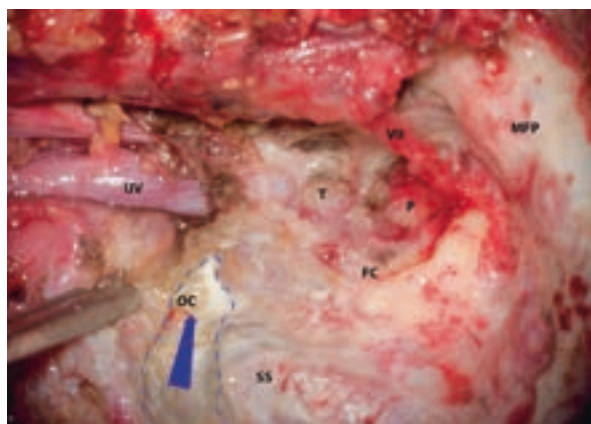

Fig. 8.66 Self-retaining retractor

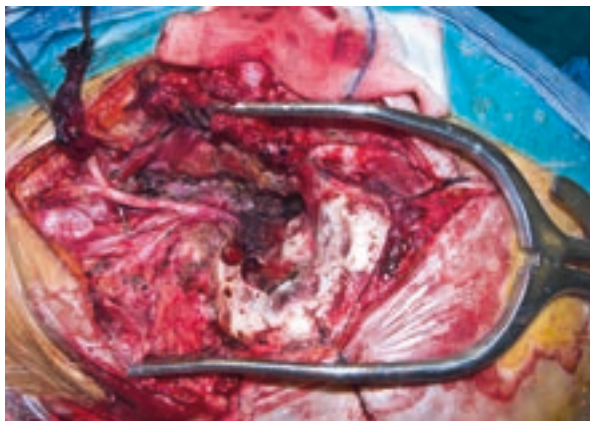
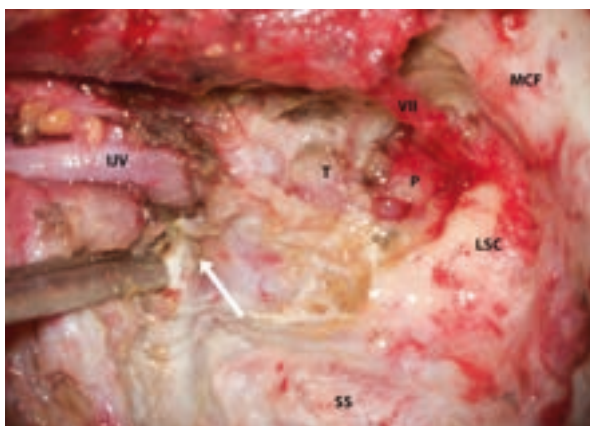


Fig. 8.67 Drilling of the jugular tubercle is completed. *IJV* internal jugular vein, *T* tumor, *P* promontory, *MCF* middle cranial fossa, *LSC* lateral semicircular canal, *VII* facial nerve, *arrow* direction to the occipital condyle



The occipital condyle contains cancellous bone with the hypoglossal canal running in a posteromedial to an anterolateral direction.

Transcondylar extension: Further extradural bone removal extends anteromedially to the jugular bulb, superior to the hypoglossal canal, which represents the jugular tubercle. This is situated approximately 5 mm above the intracranial opening of the hypoglossal canal [30] over which the IX, X, and XI nerves cross intradurally before entering the jugular fossa. This area of bone removal allows additional exposure to tumor margins from posterior to inferior and medial directions. The bipolar is then used to devascularize the tumor, minimizing the degree of bleeding from the subsequent resection. Bony dissection can be made significantly more difficult by the presence of extensive bony infiltration, resulting in continuous bleeding. The use of bipolar diathermy, diamond bur, bone wax, and judicious packing with Surgicel allows dissection to proceed. The sigmoid sinus is closed just before its junction with the transverse sinus using extraluminal packing

method (Fig. 8.68). This is facilitated by preservation of a bony shell over the proximal sigmoid sinus. The extraluminal compression prevents the blocking of the transverse sinus. If necessary the sigmoid can be slit and Surgicel packing reinforced intraluminally also. Closure of the IJV is delayed until after sigmoid closure in order to maintain venous outflow. The previously placed ties around the IJV are tied and the vein is ligated (Fig. 8.69). The vein is opened and tumor exposed (Fig. 8.70).

The final stage of surgery involves the definitive management of carotid artery involvement. Identification of the correct plane of dissection around the ICA is best performed inferiorly where the artery has a rather tough periadventitial and periosteal tissue (Fig. 8.71). A plane of cleavage is established between tumor and the carotid artery by blunt dissection, and the tumor is carefully dissected away (Figs. 8.72, 8.73, 8.74, and 8.75). The bone medial to the carotid genu is drilled to ensure removal of all infiltrated bone and to optimize superior control of the tumor

Fig. 8.68 Packing the sigmoid sinus. *MCD* middle cranial fossa dura, *SS* sigmoid sinus, *IJV* internal jugular vein

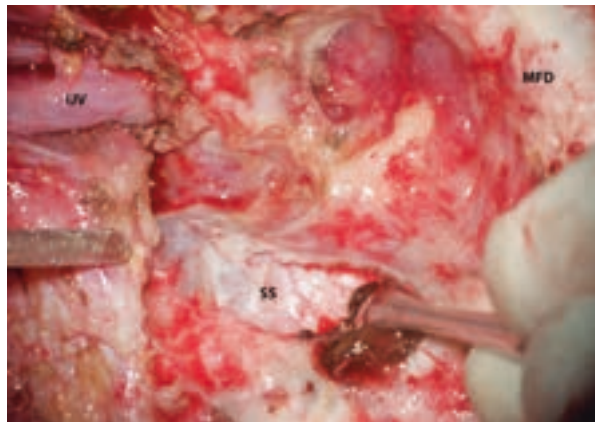


Fig. 8.69 The internal jugular vein is then double ligated and transected. This is performed following sigmoid closure to minimize venous congestion of the tumor. *MCD* middle cranial fossa dura, *SS* sigmoid sinus, *IJV* internal jugular vein

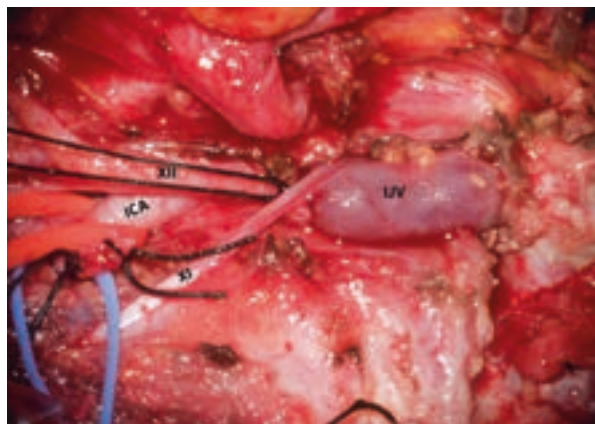


Fig. 8.70 The jugular bulb is opened to expose the tumor. *T* tumor, *XI* spinal accessory nerve, *XII* hypoglossal nerve, *VII* facial nerve

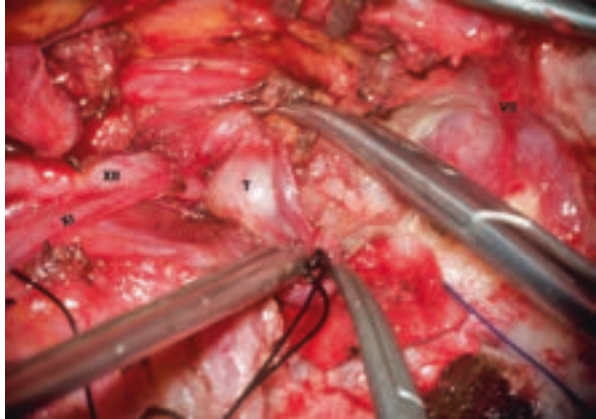


Fig. 8.71 Tumor adherent to this tissue is being dissected. There is no involvement of the ICA adventitia. *T* tumor, *ICA* internal carotid artery

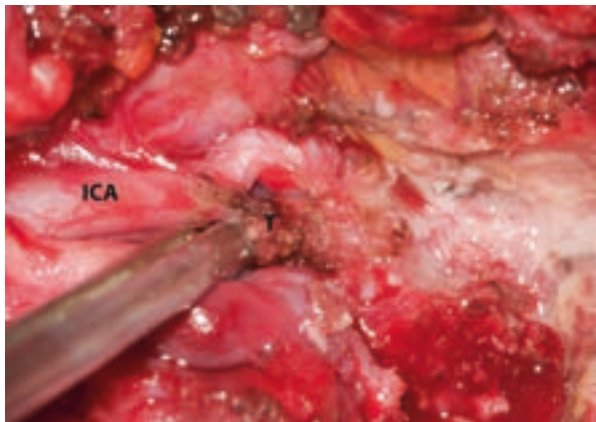


Fig. 8.72 The carotid artery has been freed up to its carotid canal. Note the periosteal layer retracted by the suction irrigator. Also note that all this dissection is performed under microscopic control. *ICA* internal carotid artery, *XII* hypoglossal nerve, *T* tumor

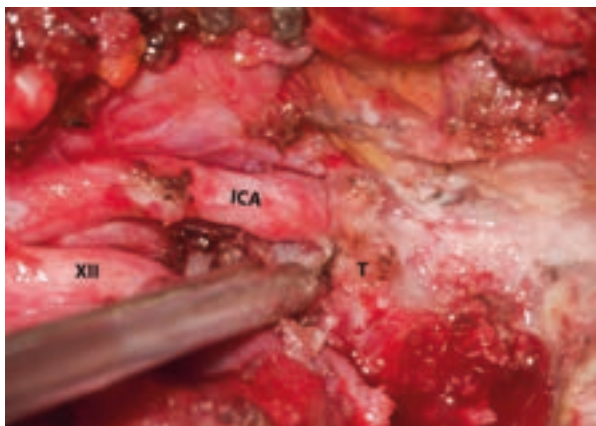


Fig. 8.73 Following further bone removal around the carotid artery, dissection is continued in a subperiosteal plane. *FN* facial nerve, *T* tumor, *ICA* internal carotid artery, *XII* hypoglossal nerve

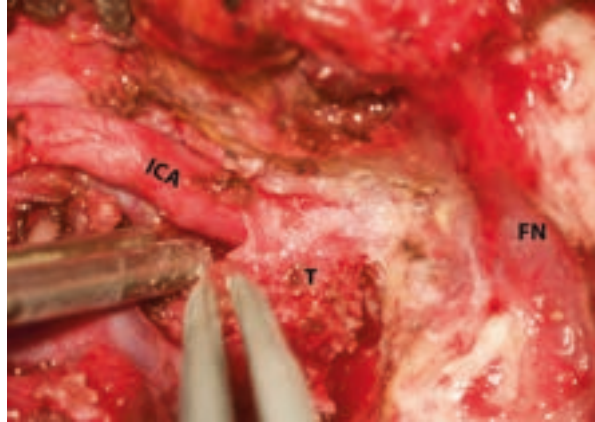


Fig. 8.74 Tumor can now be seen extending from the jugular fossa area anteromedially. A merocel patty has been placed medial to the ICA. The bone lateral and medial to the ICA has been further drilled to the level of the genu, which will allow gentle mobilization of the artery. *VII* facial nerve, *T* tumor, *ICA* internal carotid artery, *IJV* internal jugular vein, *S* Surgicel

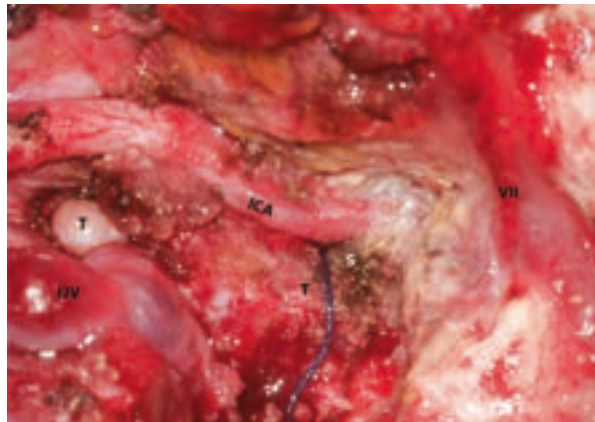
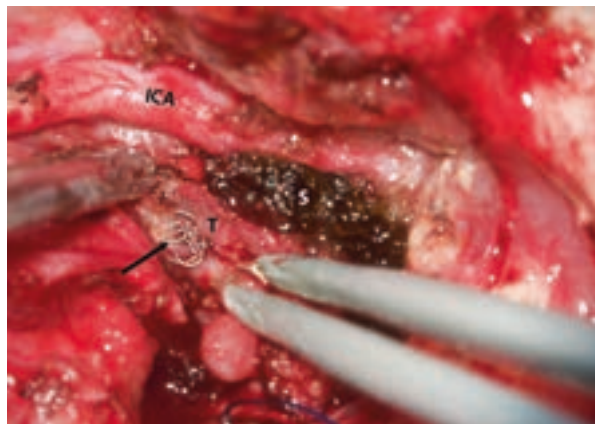

Fig. 8.75 The coils used to embolize the tumor can be seen. Note the fibrous consistency of the tumor. *ICA* internal carotid artery, *arrow* coils, *T* tumor, *S* Surgicel



margins (Fig. 8.76). The sigmoid sinus and the jugular bulb are then opened to identify the last bit of tumor attachment. The openings of the inferior petrosal sinus are identified and packed with Surgicel (Fig. 8.77). The critical point is represented by the invasion of the medial wall of the jugular bulb; in the presence of such infiltration, radical surgery requires removal of the entire bulb, with inevitable sacrifice of the lower cranial nerves. On the contrary, if the medial wall of the bulb can be preserved, the neural function can be preserved too. This technique is also referred to as intrabulbar dissection. Prior identification of the lower cranial nerves in the uninvolved neck further aids in preservation of these nerves. Care must be taken when packing branches of the inferior petrosal sinus. These can be multiplied and usually enter between the IX and X and XI nerves. If the medial wall of the jugular bulb is involved by the tumor, this is removed, but this step also puts in risk any functional lower cranial nerves (Figs. 8.78, 8.79, and 8.80). Hemostasis is achieved

Fig. 8.76 The bone medial to the carotid genu is drilled to ensure removal of all infiltrated bone and to optimize superior control of the tumor margins. *ICA* internal carotid artery, *PA* petrous apex, *FN* facial nerve

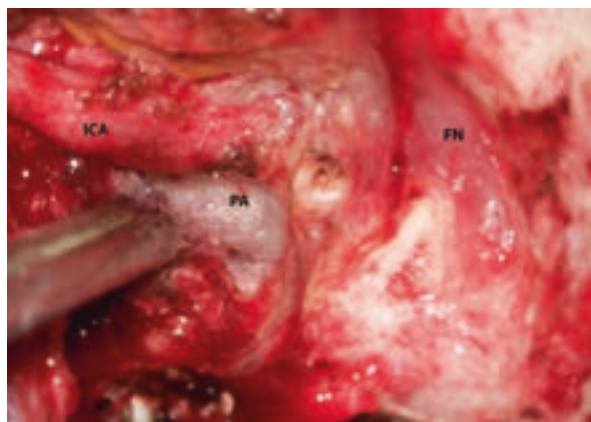

Fig. 8.77 The last bit of tumor is elevated from the medial wall of the jugular bulb. The openings of the inferior petrosal sinuses can be visualized. *T* tumor, *Co* cochlea, *SS* sigmoid sinus (medial wall)

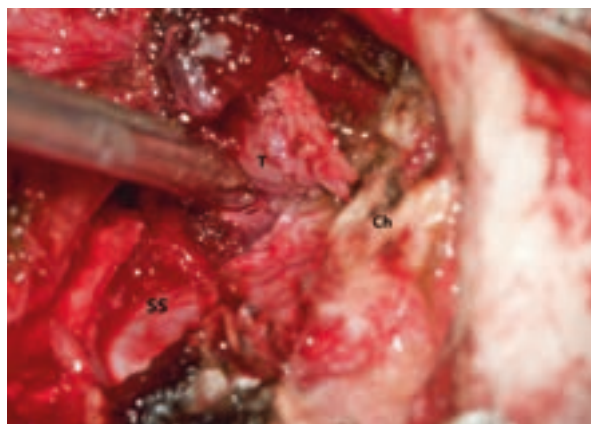


Fig. 8.78 The X and XI cranial nerves can now be seen entering the jugular fossa. Tumor has infiltrated these nerves, explaining preoperative dysfunction. *LCN* lower cranial nerves

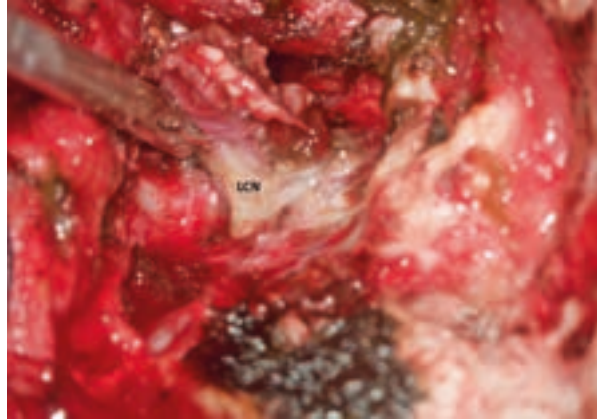


Fig. 8.79 It is important to reiterate that the degree of bony invasion is often difficult to assess even intraoperatively. *ICA* internal carotid artery, *PA* petrous apex, *FN* facial nerve, *T* tumor

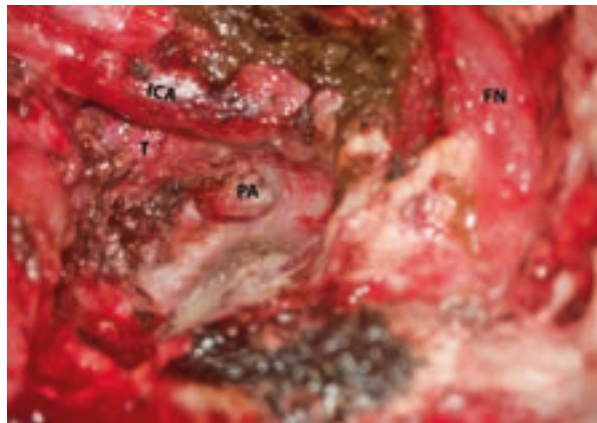
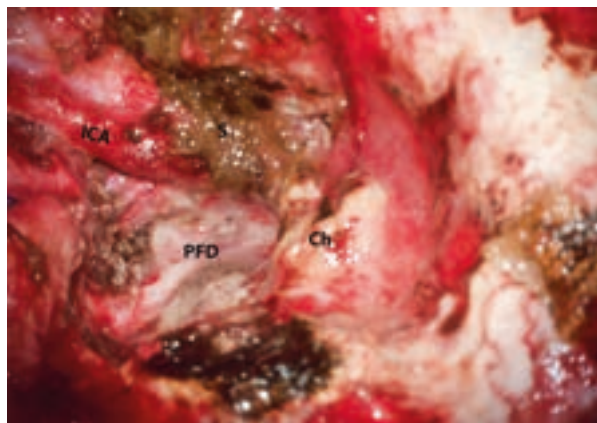


Fig. 8.80 The tumor was removed, with transection of the infiltrated nerves. Further bone removal of the lower clivus is performed to ensure complete removal of infiltrated bone. *ICA* internal carotid artery, *Co* cochlea, *S* Surgicel, *PFD* posterior fossa dura



using bipolar coagulation and Surgicel packing. The Eustachian tube is closed with periosteum plug. The cavity is obliterated with abdominal fat. The dead space is filled with abdominal fat. The skin is closed with sutures in a watertight fashion (Figs. 8.81 and 8.82).

This patient suffered postoperative paralysis of the IX, X, XI, XII, and lower cranial nerves, but she achieved very good contralateral compensation after rehabilitation. The FN function was grade III and the patient had normal bone conduction. The genetic study was negative for hereditary genetic traits (Figs. 8.83 and 8.84).

Fig. 8.81 Cavity obliteration with abdominal fat

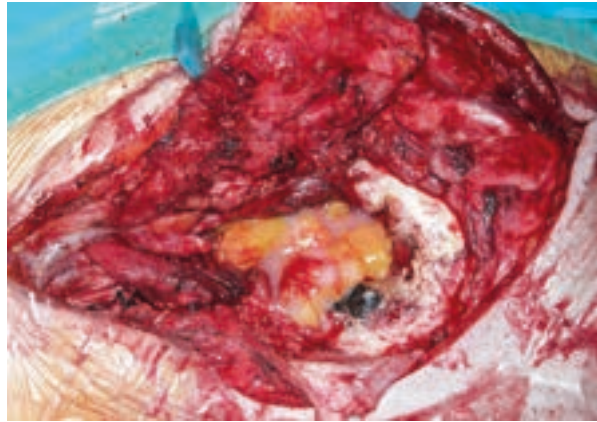


Fig. 8.82 Meticulous closure of the musculofascial flaps

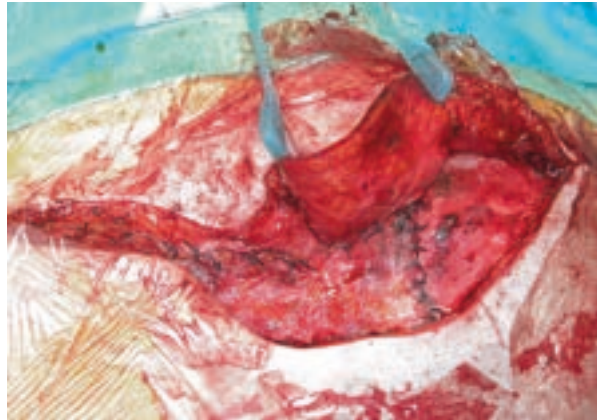


Fig. 8.83 Postoperatively CT scan shows the extent of bone removal

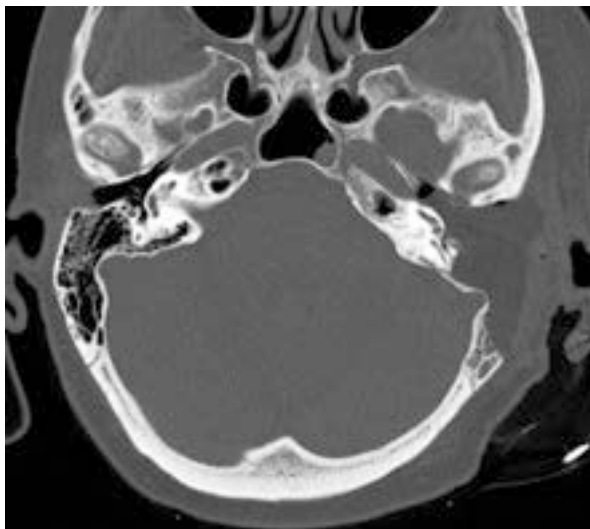
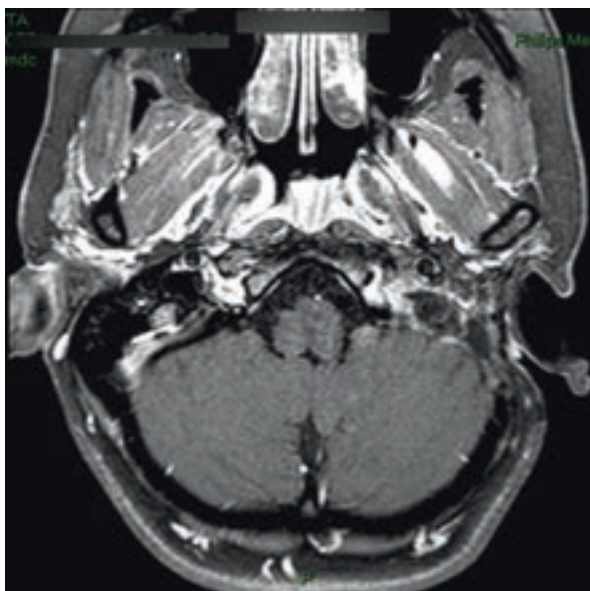


Fig. 8.84 Postoperatively MRI shows complete tumor clearance



Representative Case 2 with Detailed Description and Illustration of Surgical Steps

Two-stage removal in a case of a complex paraganglioma of the skull base with a class C3Di2 TJP and a stage I vagal paraganglioma after permanent balloon occlusion of the internal carotid artery.

Complex paragangliomas include extensive tumors; tumors with large intradural extension; tumors involving the cavernous sinus, ICA, or vertebral artery; and previously operated or irradiated tumors (Fig. 8.85). Also included are tumors with a single carotid artery, dominant or unilateral sigmoid sinus on the side of the lesion, or bilateral or multiple tumors. It is difficult to decide on the treatment for these tumors, and accurate preoperative surgical planning is mandatory. Here we present one such case.

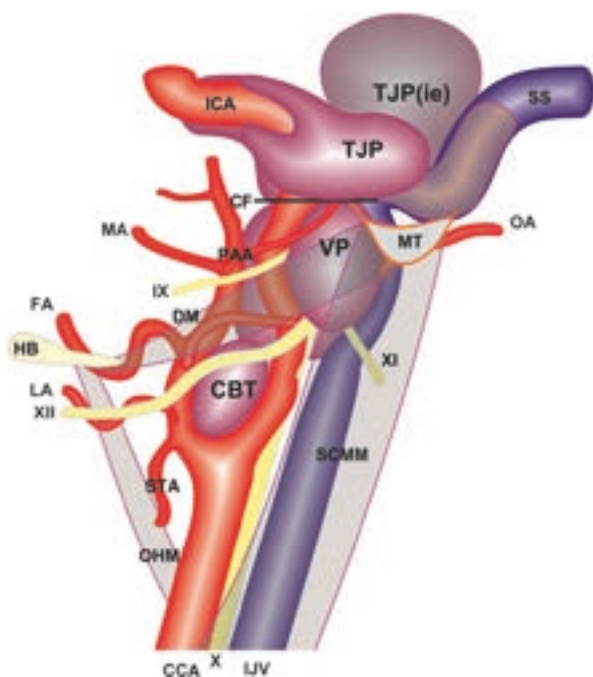
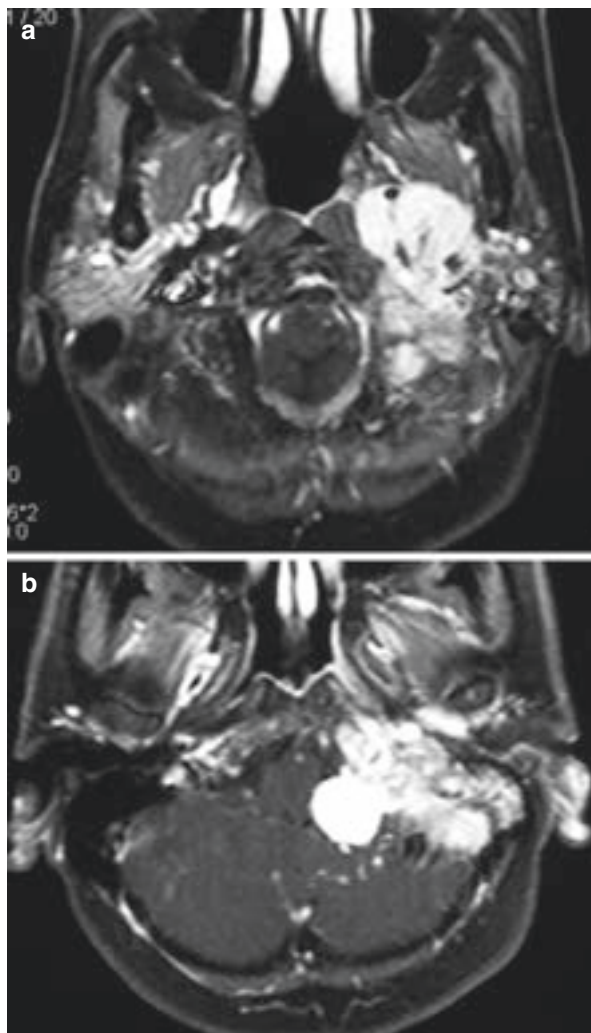


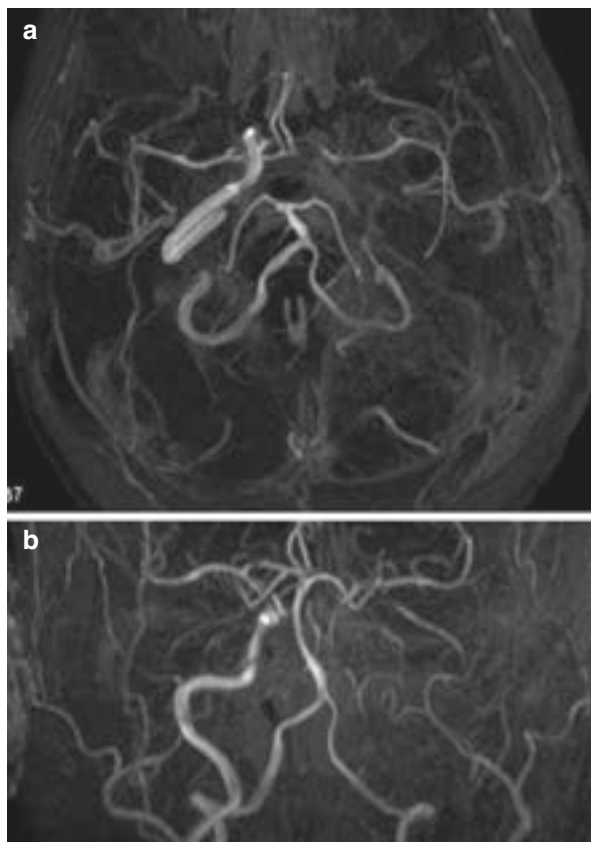
Fig. 8.85 Illustration for complex tympanojuvular paragangliomas. *TJP* tympanojuvular paraganglioma, *TJP (ie)* intradural or extradural TJP, *CF* carotid foramen, *VP* vagal paraganglioma, *CBT* carotid body tumor, *OHM* omohyoid muscle, *CCA* common carotid artery, *IJV* internal jugular vein, *ICA* internal carotid artery, *HB* hyoid bone, *PAA* posterior auricular artery, *MT* mastoid tip, *OA* occipital artery, *IX* glossopharyngeal nerve, *X* vagus nerve, *XI* spinal accessory nerve, *XII* hypoglossal nerve, *MA* maxillary artery, *DM* posterior belly of the digastric muscle, *FA* facial artery, *LA* lingual artery, *SCMM* sternocleidomastoid muscle

Fig. 8.86 Preoperative MRI showing an extensive jugular fossa mass with (a) infratemporal fossa and (b) jugular fossa and intradural involvement



A 52-year-old lady presented with a 3–4-year history of dysphonia, progressive hearing loss, and pulsatile tinnitus. She had no family history. Otoscopy revealed a keratin-covered mass occupying the medial compartment of the external auditory canal. She showed paralysis of vagus and hypoglossal nerve and had a dead ear. Axial T1-enhanced MRI scans revealed a large hypervascular mass occupying the post-styloid parapharyngeal space with complete encasement of the carotid artery (Fig. 8.86). At a higher level, a large intradural component was seen extending through the medial aspect of the jugular fossa with dural infiltration along the entire posterior face of the petrous bone. MRA showed an absence of the left ICA, but

Fig. 8.87 (a, b) MRA showing the absence of the left ICA, but adequate collateral supply through the circle of Willis



adequate collateral supply through the circle of Willis (Fig. 8.87). Angiography confirmed the likelihood of two lesions (Fig. 8.88a, b). In summary, the preoperative findings were a stage I of large vagal paraganglioma and a C3Di2 TJP (Figs. 8.89 and 8.90). Due to the circumferential involvement of the ICA both in its cervical and intratemporal segments, the patient was assessed for permanent balloon occlusion followed by a two-staged resection.

The blind sac closure, neck dissection, and exposure of the extratemporal segment of the FN were carried out as described before. The important neurovasculature in the neck was identified. Tumor in the middle ear was extensively diathermized to control bleeding prior to rerouting of the FN. The FN was mobilized and rerouted anteriorly. The styloid process was cut along with the attached muscles and ligaments to optimize ICA exposure. The sigmoid sinus was extraluminally packed and the IJV was ligated in the neck. Further drilling of the bone was done posteroinferi-

Fig. 8.88 (a) The ovoid mass represents a large vagal paraganglioma (*white arrow*), with the poorly defined tumor blush posterosuperiorly representing a jugular paraganglioma (*black arrow*). Tumor can be seen involving the horizontal segment of the ICA. (b) Angiogram of a case of a vagal paragangliomas combined with a tympanojugular paraganglioma (*lateral view*). The right internal carotid artery shows evidence of stenosis (*thin arrow*) and displacement (*thick arrow*) due to the vagal paraganglioma

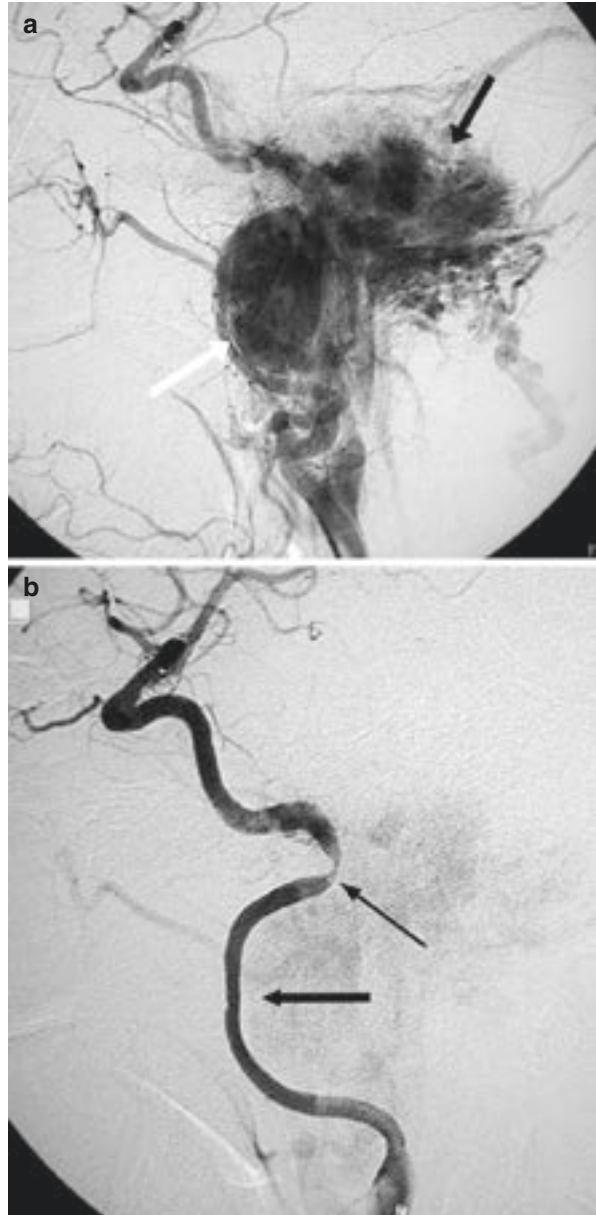
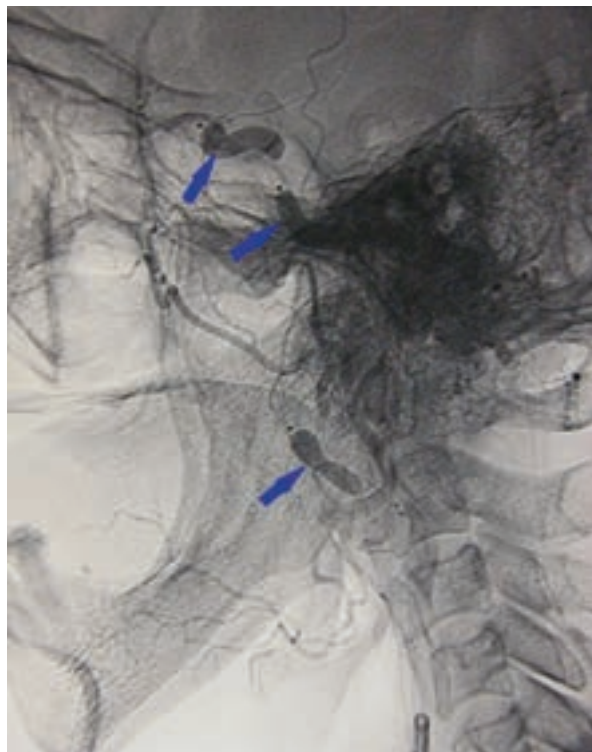


Fig. 8.89 Preoperative permanent balloon occlusion. The proximal and distal balloons (*arrows*) can be seen in place prior to deployment



only to the sigmoid and bulb, and tumor was seen to be extending toward the occipital condyle (Fig. 8.91). The feeding artery (the ascending pharyngeal artery) and the occluded ICA were ligated with vascular clips (Fig. 8.92). The ICA was found to be completely encircled and infiltrated by the tumor. Extensive bone removal was performed around the horizontal segment of the ICA to the foramen lacerum to expose the horizontal and vertical portions of the petrous ICA (Fig. 8.93). The ICA was resected at the level of the foramen lacerum (Fig. 8.94). The vagal paraganglioma was then approached and excised in toto with the involved ICA and the lower cranial nerves X, XI, and XII (Figs. 8.95 and 8.96). Postoperatively the patient developed an additional XI cranial nerve palsy. The FN was HB grade III within 3 months after surgery. Postoperative imaging showed complete excision of the extradural part of the tumor with the intradural component left in situ (Fig. 8.97a, b).

In the second stage after 6 months, a translabyrinthine-transclival approach was employed to remove the intradural component of the tumor. A large postauricular C-shaped skin incision was performed. An inferiorly based U-shaped musculoperi-

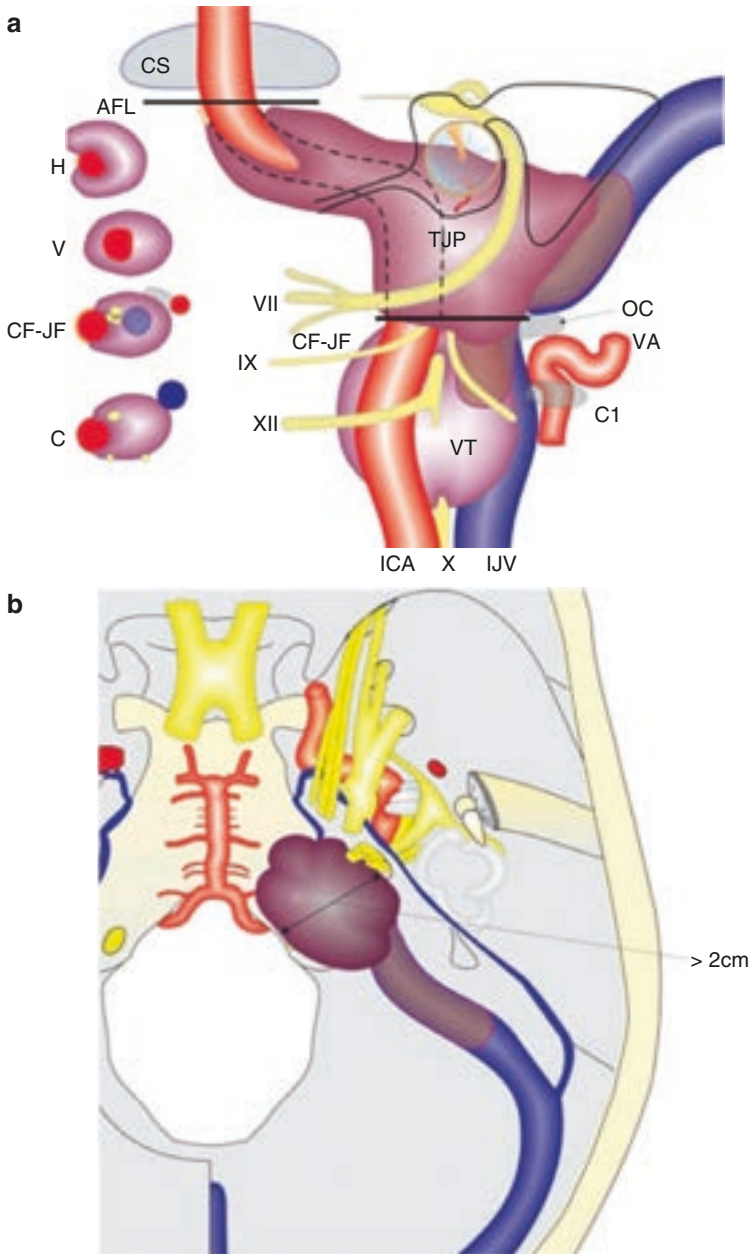


Fig. 8.90 Illustrative diagram of the lesion. (a) Class C3Di2 TJP on the left side. (b) Intradural component

Fig. 8.91 Note the wide exposure of the extended jugular fossa area due to anterior rerouting of the FN and excision of the styloid process. *IJV* internal jugular vein (ligated), *T* tumor, *OC* occipital condyle, *LSC* lateral semicircular canal, *SS* sigmoid sinus

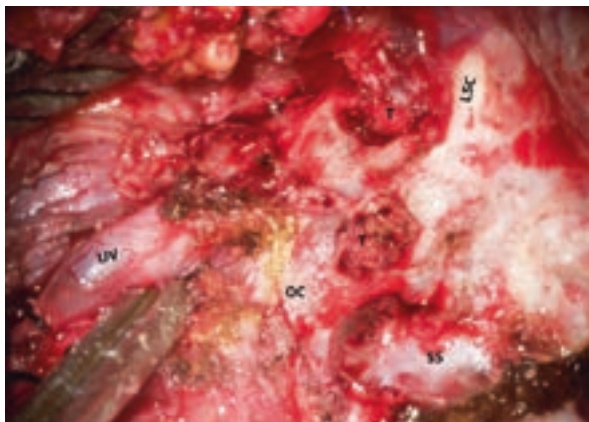


Fig. 8.92 A vascular clip has been used to close the balloon-occluded ICA. *ICA* internal carotid artery, *ECA* external carotid artery, *AFA* ascending pharyngeal artery

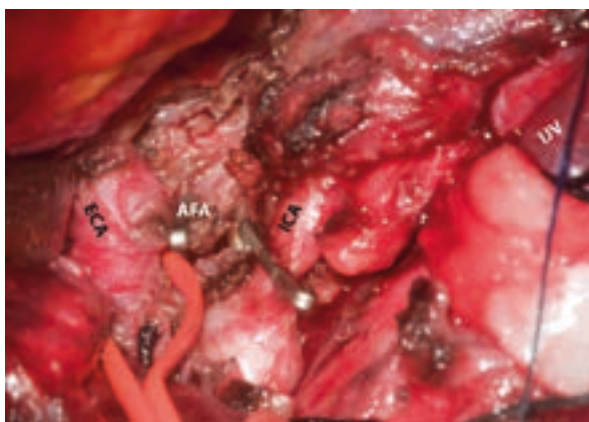

Fig. 8.93 The vertical and horizontal portion of the ICA is skeletonized. Note the relationship of the cochlea to the ICA. *ICA(V)* vertical segment of the ICA, *G* carotid genu, *Co* cochlea, *LSC* lateral semicircular canal, *T* tumor

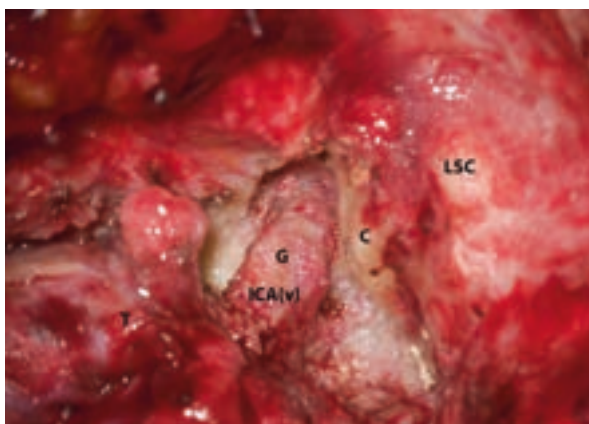


Fig. 8.94 The ICA has been transected at the level of the foramen lacerum, with the cell of the petrous apex now visible. The medial bony carotid canal was seen. The essentially bloodless dissection is a testament to the permanent balloon occlusion of the ICA. Superior control of the tumor has now been attained. *T* tumor, *FL* foramen lacerum, *CC* carotid canal, *LSC* lateral semicircular canal, *Co* cochlea

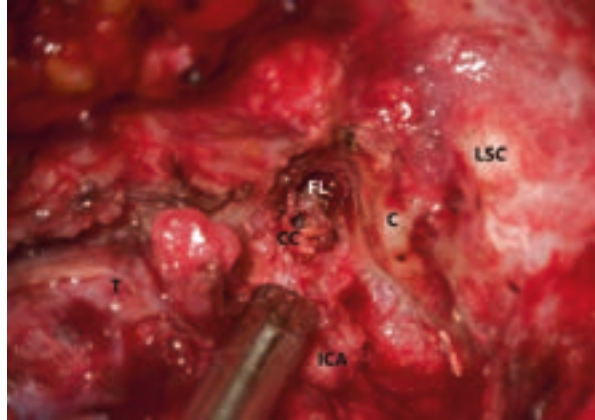


Fig. 8.95 The vagal paraganglioma is now addressed. The ICA is within this large tumor mass. *IJV* internal jugular vein

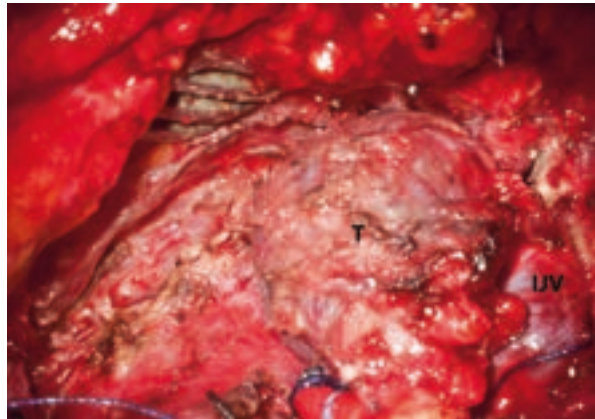
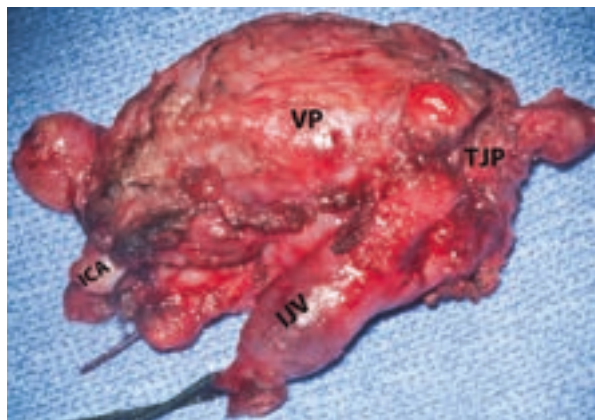


Fig. 8.96 The removed tumor, with IJV and ICA embedded. *ICA* internal carotid artery, *IJV* internal jugular vein, *VP* vagal paraganglioma, *TJP* tympanojugular paraganglioma



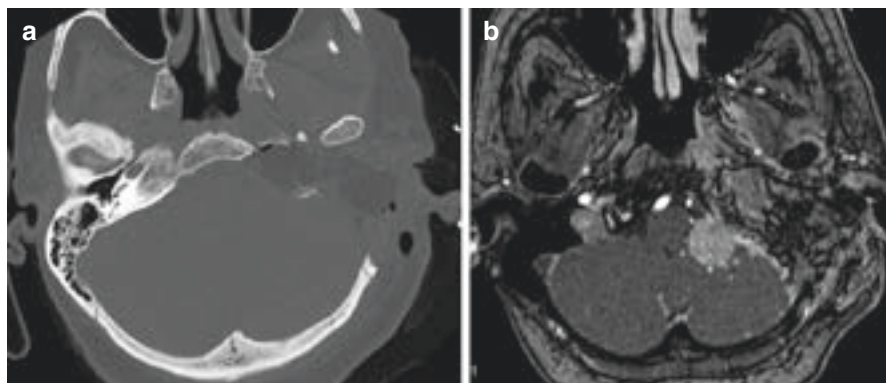
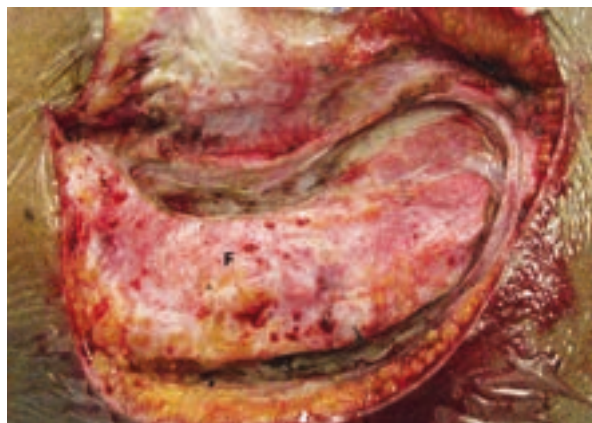


Fig. 8.97 Post-op imaging shows. (a) CT illustrating that the entire petrous apex surrounding the ICA has been removed. (b) Enhanced axial T1 MRI revealing complete removal of the extradural component, with the residual intradural tumor and extensive dural enhancement seen

Fig. 8.98 A large postauricular C-shaped skin incision was performed. An inferiorly based U-shaped musculoperiosteal flap (F) is used in this approach



osteal flap (F) is used in this approach (Fig. 8.98). The previously dissected mastoid cavity was exposed, with care being taken not to damage the rerouted FN (Fig. 8.99). The middle and posterior fossa dura are uncovered, with the labyrinthine block providing a ready landmark (Fig. 8.100). The labyrinthectomy was completed, and the IAC was skeletonized (Fig. 8.101). The posterior fossa dura lateral to the porus acusticus was widely opened (Fig. 8.102). The tumor was seen extending to involve the acousticofacial bundle. The tumor was coagulated on all surfaces using a bipolar and shrunk. It is then dissected carefully from the anterior inferior cerebellar artery, the brain stem, the FN, and the lower cranial nerves (Figs. 8.103, 8.104, 8.105, 8.106, and 8.107). The closure of the musculoperiosteal flap was performed with abdominal fat having been placed through the dural defect into the intradural space (Fig. 8.108). Postoperative MRI showed complete tumor clearance (Fig. 8.109a, b).

Fig. 8.99 Care must be taken to avoid injury to the anteriorly rerouted FN during the soft tissue approach. *PFD* posterior fossa dura, *L* labyrinth

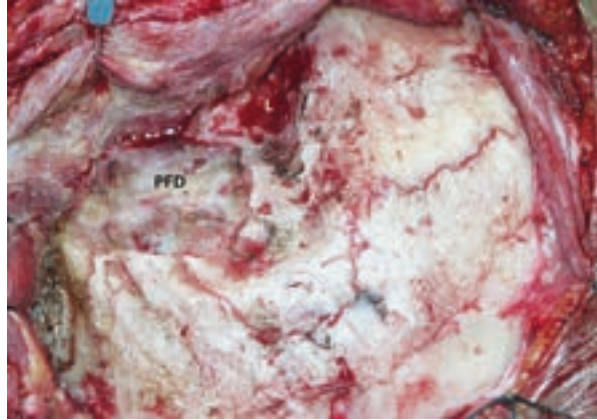


Fig. 8.100 Note that the sigmoid sinus was sacrificed at the previous surgery. *LSC* lateral semicircular canal, *PSC* posterior semicircular canal, *SSC* superior semicircular canal, *MFD* middle fossa dura, *PFD* posterior fossa dura, *SDA* sinodural angle

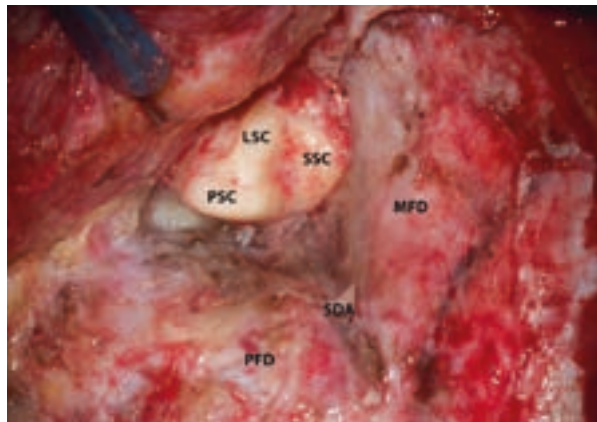


Fig. 8.101 The labyrinthectomy has been completed, and IAC is skeletonized. *IAC* internal auditory canal, *MFD* middle fossa dura, *PFD* posterior fossa dura, *SDA* sinodural angle

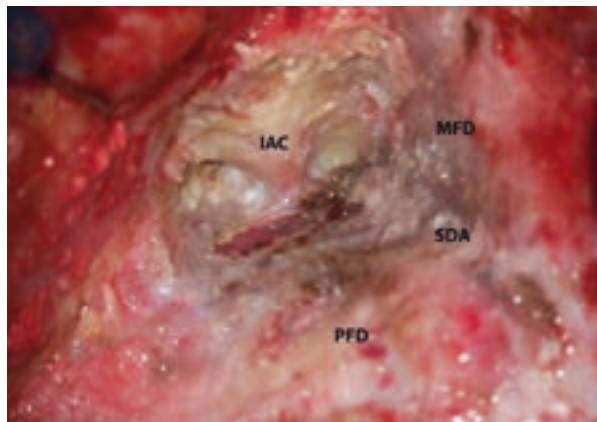


Fig. 8.102 The wide dural resection has been performed, with exposure of the large intradural tumor. *IAC* internal auditory canal, *T* tumor, *Cbl* cerebellum, *MFD* middle fossa dura, *PFD* posterior fossa dura

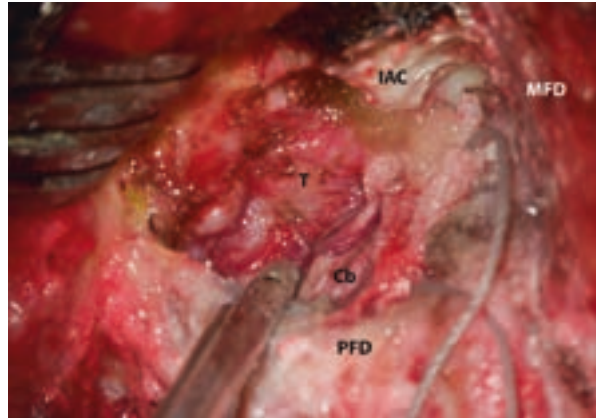


Fig. 8.103 The clivus anterior to the tumor was drilled until the normal cancellous bone has been exposed. *IAC* internal auditory canal, *T* tumor, *CL* clivus, *PFD* posterior fossa dura

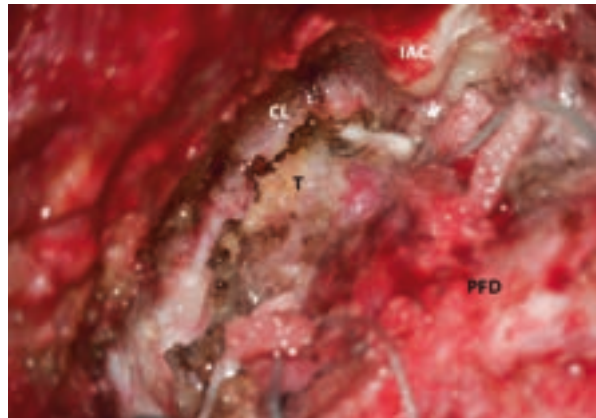


Fig. 8.104 Removal of tumor has been performed from a superior direction. Note the gradual dissection of tumor from the anterior inferior cerebellar artery. *IAC* internal auditory canal, *T* tumor, *CL* clivus, *AICA* anterior inferior cerebellar artery, *BS* brain stem, *PFD* posterior fossa dura

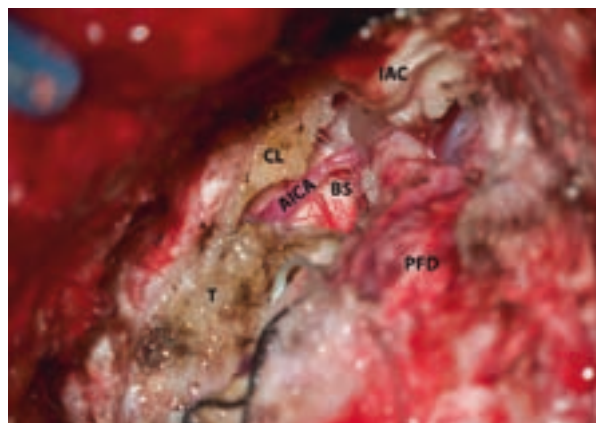


Fig. 8.105 The debulked tumor is gradually peeled from the brain stem and vasculature. The extensive vascularization can be appreciated. *T* tumor, *BS* brain stem, *VP* venous plexus of the tumor, *LCN* lower cranial nerve IX

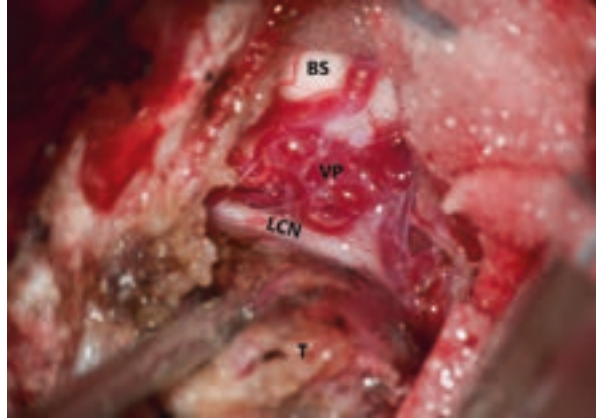

Fig. 8.106 The inferior pole of the tumor (*T*) is now approached. Note the extensive devascularization of the tumor by surface bipolarization. A merocel (*M*) patty is introduced between the tumor and brain stem. *R* cerebellar retractor, *CL* clivus, *T* tumor, *BS* brain stem, *M* merocel

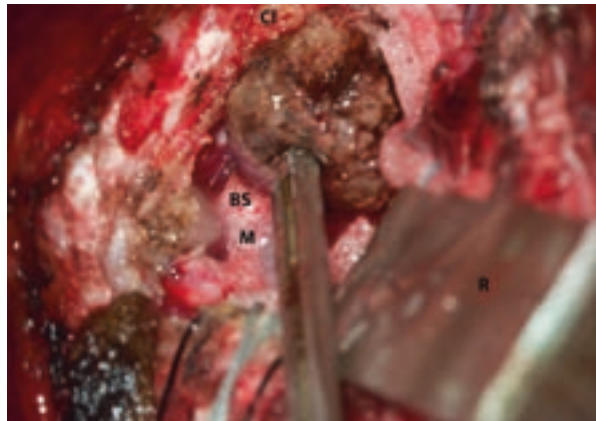


Fig. 8.107 The tumor has now been completely removed, with the VII or VIII complex seen superiorly. *CL* clivus, *BS* brain stem, *AICA* anterior inferior cerebellar artery, *PFD* posterior fossa dura

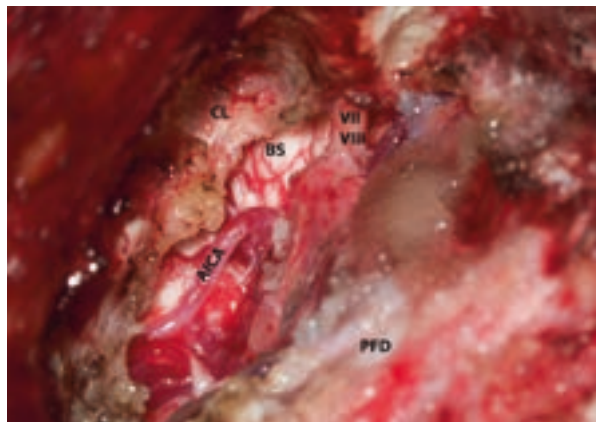

Fig. 8.108 A watertight closure is ensured

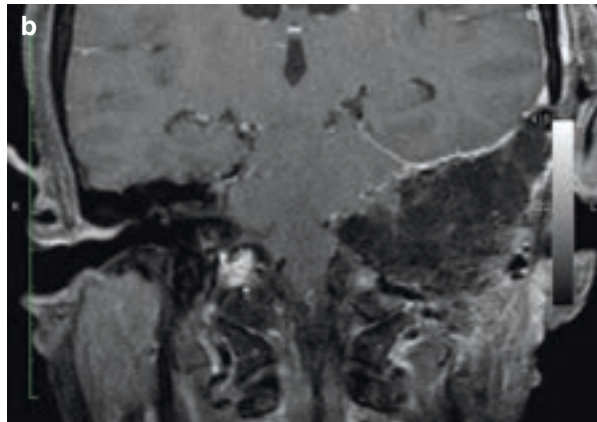
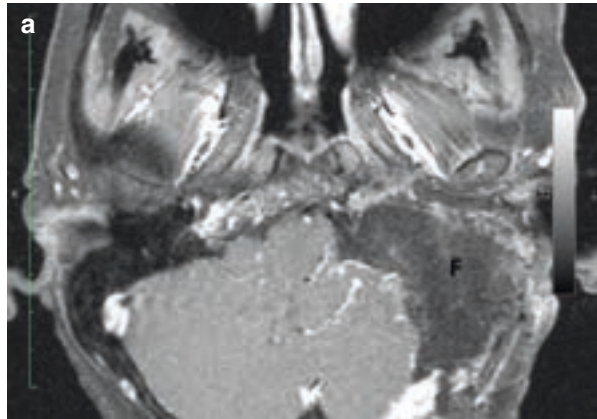
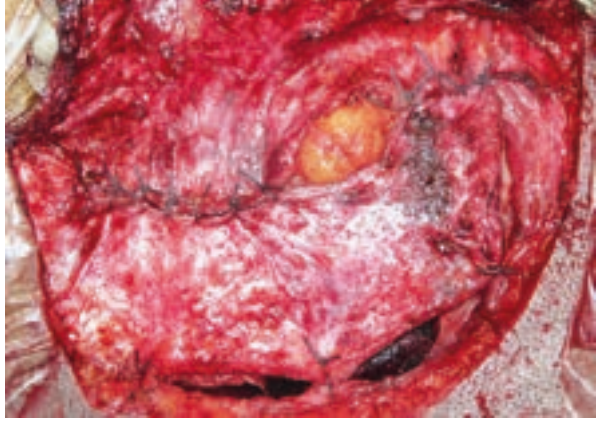

Fig. 8.109 (a) Gd-enhanced MRI axial view with fat suppression after surgery shows that there is no residual tumor. (b) MRI, coronal view. Total tumor removal is completed. *F* abdominal fat

References

1. Shin SH, Sivalingam S, De Donato G, Falcioni M, Piazza P, Sanna M. Vertebral artery involvement by tympanojugular parangliomas: management and outcomes with a proposed addition to the Fisch classification. *Audiol Neurootol*. 2012;17:92–104.
2. Moe KS, Li D, Linder TE, Schmid S, Fisch U. An update on the surgical treatment of temporal bone paranglioma. *Skull Base Surg*. 1999;9:185–94.
3. Sanna M, Shin SH, Piazza P, et al. Infratemporal fossa approach type a with transcondylar-transtubercular extension for Fisch type C2 to C4 tympanojugular parangliomas. *Head Neck*. 2014;36(11):1581–8.
4. Sanna M, Flanagan S. The combined transmastoid retro- and infralabyrinthine transjugular transcondylar transtubercular high cervical approach for resection of glomus jugulare tumors. *Neurosurgery*. 2007;61:E1340. author reply E1340
5. Patel SJ, Sekhar LN, Cass SP, Hirsch BE. Combined approaches for resection of extensive glomus jugulare tumors. A review of 12 cases. *J Neurosurg*. 1994;80:1026–38.
6. Witiak DG, Pensak ML. Limitations to mobilizing the intrapetrous carotid artery. *Ann Otol Rhinol Laryngol*. 2002;111:343–8.
7. Jackson CG, Kaylie DM, Coppit G, Gardner EK. Glomus jugulare tumors with intracranial extension. *Neurosurg Focus*. 2004;17:E7.
8. Fisch U, Pillsbury HC. Infratemporal fossa approach to lesions in the temporal bone and base of the skull. *Arch Otolaryngol*. 1979;105:99–107.
9. Oghalai JS, Leung MK, Jackler RK, McDermott MW. Transjugular craniotomy for the management of jugular foramen tumors with intracranial extension. *Otol Neurotol*. 2004;25:570–579; discussion 579.
10. Liu JK, Sameshima T, Gottfried ON, Couldwell WT, Fukushima T. The combined transmastoid retro- and infralabyrinthine transjugular transcondylar transtubercular high cervical approach for resection of glomus jugulare tumors. *Neurosurgery*. 2006;59:ONS115–25. discussion ONS115–125
11. Al-Mefty O, Teixeira A. Complex tumors of the glomus jugulare: criteria, treatment, and outcome. *J Neurosurg*. 2002;97:1356–66.
12. Cokkeser Y, Brackmann DE, Fayad JN. Conservative facial nerve management in jugular foramen schwannomas. *Am J Otol*. 2000;21:270–4.
13. Ramina R, Maniglia JJ, Fernandes YB, Paschoal JR, Pfeilsticker LN, Coelho NM. Tumors of the jugular foramen: diagnosis and management. *Neurosurgery*. 2005;57:59–68. discussion 59–68
14. Borba LA, Ale-Bark S, London C. Surgical treatment of glomus jugulare tumors without rerouting of the facial nerve: an infralabyrinthine approach. *Neurosurg Focus*. 2004;17:E8.
15. George B, Tran PB. Surgical resection of jugulare foramen tumors by juxtacondylar approach without facial nerve transposition. *Acta Neurochir*. 2000;142:613–20.
16. Leonetti JP, Anderson DE, Marzo SJ, Origiano TC, Shirazi M. Intracranial schwannomas of the lower cranial nerves. *Otol Neurotol*. 2006;27:1142–5.
17. Sanna M, Falcioni M. Conservative facial nerve management in jugular foramen schwannomas. *Am J Otol*. 2000;21:892.
18. Farris J. Transcanal hypotympanotomy: management of glomus tumours of the middle ear and hypotympanum. *Oper Tech Otolaryngol Head Neck Surg*. 1996;7:113–7.
19. Farris JB. Glomus tumors. Postauricular hypotympanotomy and hypotympanoplasty. *Arch Otolaryngol*. 1967;86:367–73.
20. Jackler RK, Brackmann DE. *Neurotology*. Philadelphia: Elsevier Mosby; 2005.
21. Shambaugh GE Jr. Surgical approach for so-called glomus jugulare tumors of the middle ear. *Laryngoscope*. 1955;65:185–98.
22. Gilbert ME, Shelton C, McDonald A, et al. Meningioma of the jugular foramen: glomus jugulare mimic and surgical challenge. *Laryngoscope*. 2004;114:25–32.

23. Pensak ML, Jackler RK. Removal of jugular foramen tumors: the fallopian bridge technique. *Otolaryngol Head Neck Surg.* 1997;117:586–91.
24. Sanna M, Piazaa P, Shin SH, Flanagan S, Mancini F. *Microsurgery of skull base paraganglioma.* Stuttgart: Thieme; 2013. p. 555–677.
25. Aslan A, Falcioni M, Russo A, et al. Anatomical considerations of high jugular bulb in lateral skull base surgery. *J Laryngol Otol.* 1997;111:333–6.
26. Lustig LR, Jackler RK. The variable relationship between the lower cranial nerves and jugular foramen tumors: implications for neural preservation. *Am J Otol.* 1996;17:658–68.
27. Arnavotic KI, Al-Mefty O. Primary meningiomas of the jugular fossa. *J Neurosurg.* 2002;97:12–20.
28. Kadri PA, Al-Mefty O. Surgical treatment of dumbbell-shaped jugular foramen schwannomas. *Neurosurg Focus.* 2004;17:E9.
29. Wen HT, Rhoton AL Jr, Katsuta T, de Oliveira E. Microsurgical anatomy of the transcondylar, supracondylar, and paracondylar extensions of the far-lateral approach. *J Neurosurg.* 1997;87:555–85.
30. Rhoton AL Jr. The far-lateral approach and its transcondylar, supracondylar, and paracondylar extensions. *Neurosurgery.* 2000;47:S195–209.
31. Banerji D, Behari S, Jain VK, Pandey T, Chhabra DK. Extreme lateral transcondylar approach to the skull base. *Neurol India.* 1999;47:22–30.
32. Babu RP, Sekhar LN, Wright DC. Extreme lateral transcondylar approach: technical improvements and lessons learned. *J Neurosurg.* 1994;81:49–59.
33. Salas E, Sekhar LN, Ziyal IM, Caputy AJ, Wright DC. Variations of the extreme-lateral craniocervical approach: anatomical study and clinical analysis of 69 patients. *J Neurosurg.* 1999;90:206–19.
34. Spektor S, Anderson GJ, McMenomey SO, Horgan MA, Kellogg JX, Delashaw JB Jr. Quantitative description of the far-lateral transcondylar transtuberular approach to the foramen magnum and clivus. *J Neurosurg.* 2000;92:824–31.
35. Cokkeser Y, Naguib MB, Kizilay A. Management of the vertebral artery at the craniocervical junction. *Otolaryngol Head Neck Surg.* 2005;133:84–8.
36. Sekhar LNJ. *Surgery of cranial base tumours.* New York: Raven Press; 1993.
37. Fisch U, Mattox D. *Microsurgery of the skull base.* Verlag: Georg Thieme; 1988.
38. Fisch U. Infratemporal fossa approach for glomus tumors of the temporal bone. *Ann Otol Rhinol Laryngol.* 1982;91:474–9.
39. Sanna M, Jain Y, De Donato G, Rohit LL, Taibah A. Management of jugular paragangliomas: the Gruppo Otologico experience. *Otol Neurotol.* 2004;25:797–804.
40. Fisch U, Fagan P, Valavanis A. The infratemporal fossa approach for the lateral skull base. *Otolaryngol Clin North Am.* 1984;17:513–52.
41. Sanna M, Piazza P, De Donato G, Menozzi R, Falcioni M. Combined endovascular-surgical management of the internal carotid artery in complex tympanojugular paragangliomas. *Skull Base.* 2009;19:26–42.
42. Sanna M, Khrais T, Menozzi R, Piazza P. Surgical removal of jugular paragangliomas after stenting of the intratemporal internal carotid artery: a preliminary report. *Laryngoscope.* 2006;116:742–6.
43. Piazza P, Di Lella F, Menozzi R, Bacciu A, Sanna M. Absence of the contralateral internal carotid artery: a challenge for management of ipsilateral glomus jugulare and glomus vagale tumors. *Laryngoscope.* 2007;117:1333–7.
44. Konishi M, Piazza P, Shin SH, Sivalingam S, Sanna M. The use of internal carotid artery stenting in management of bilateral carotid body tumors. *Eur Arch Otorhinolaryngol.* 2011;268:1535–9.
45. Geibprasert S, Pongpech S, Armstrong D, Krings T. Dangerous extracranial-intracranial anastomoses and supply to the cranial nerves: vessels the neurointerventionalist needs to know. *AJNR Am J Neuroradiol.* 2009;30:1459–68.