

November 23nd, 2017

138 Hands-on Course in LATERAL SKULL BASE SURGERY

November 20th-24th 2017

GRUPPO OTOLOGICO

Piacenza – Rome

Italy

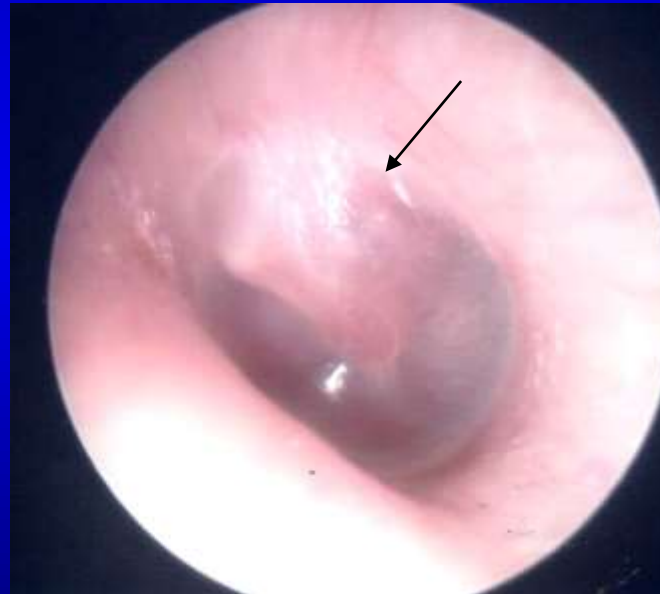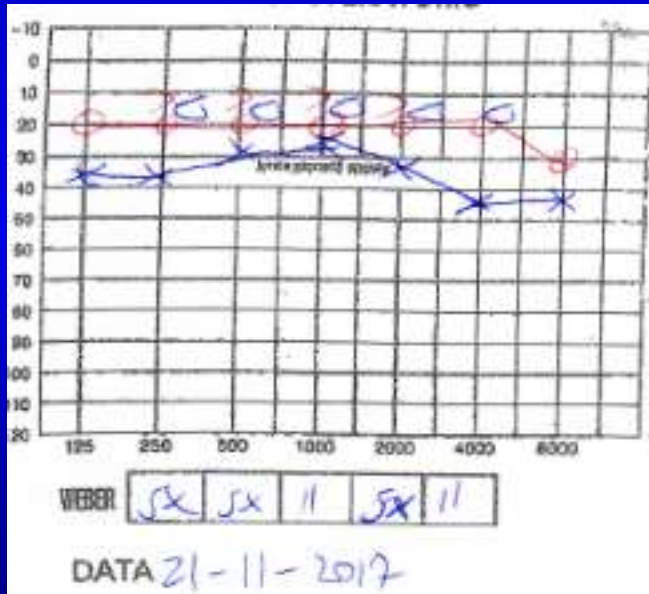


CASE #1 – Recurrent FN palsy

- **Age** – 29 years
- **Sex** – Female
- **History**
 - 2014: left FN palsy, completely recovered after medical therapy
 - 02/2017: recurrence → partial recovery (HB IIIB)
 - Dizziness
 - No other CNs dysfunction

CASE #1 – Recurrent FN palsy

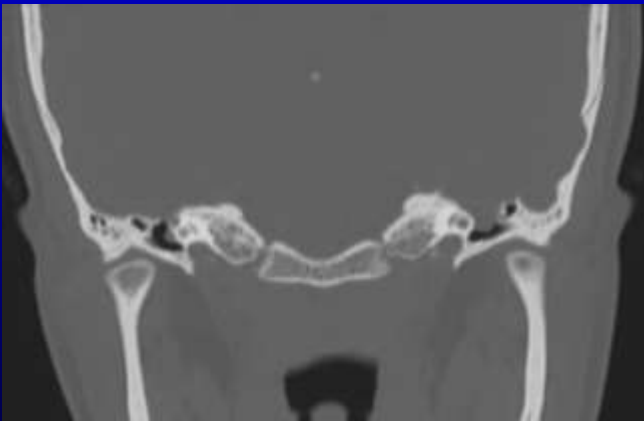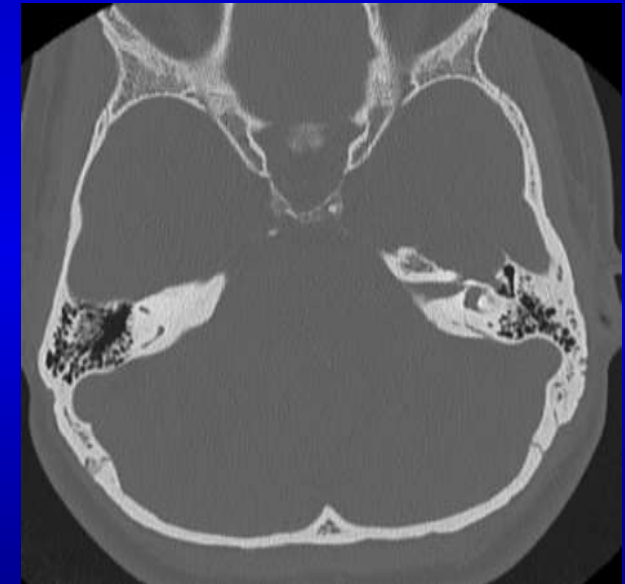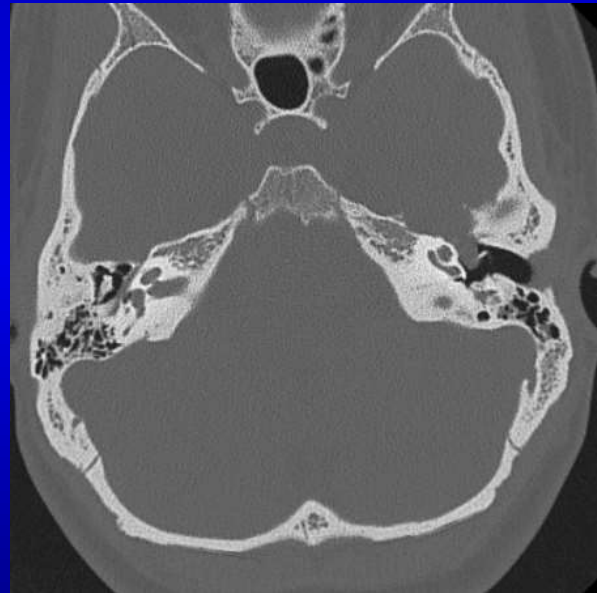
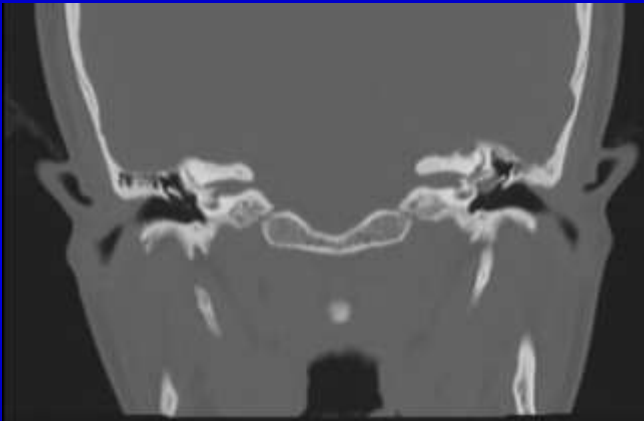- Hearing Test & otoscopy



- Left FN palsy grade IIIB HB

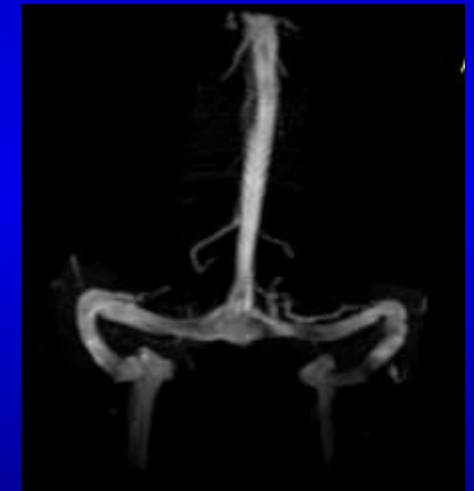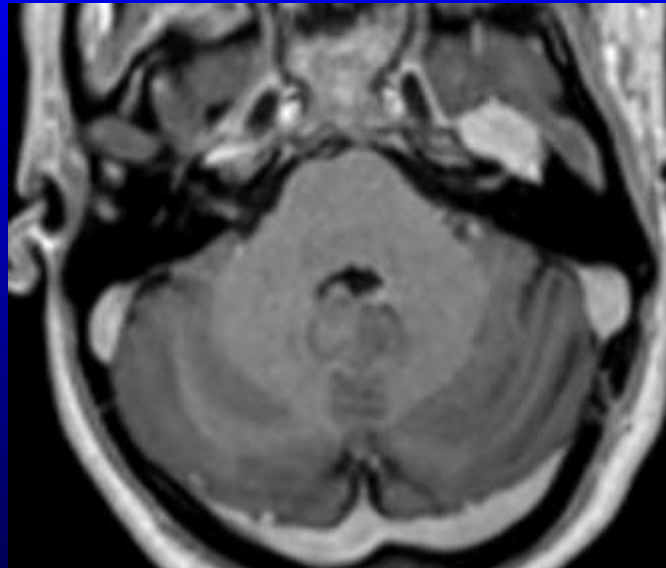
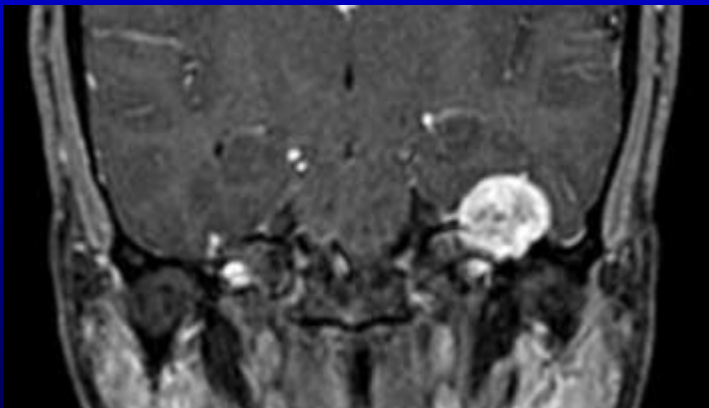
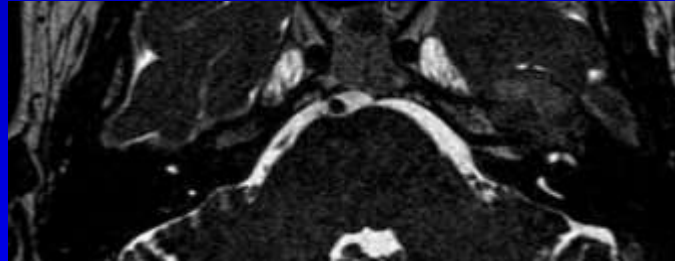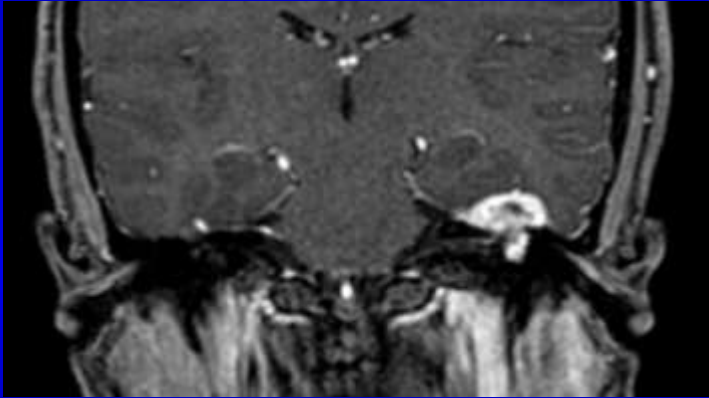
CASE #1 – Recurrent FN palsy

- Radiological investigation - CT



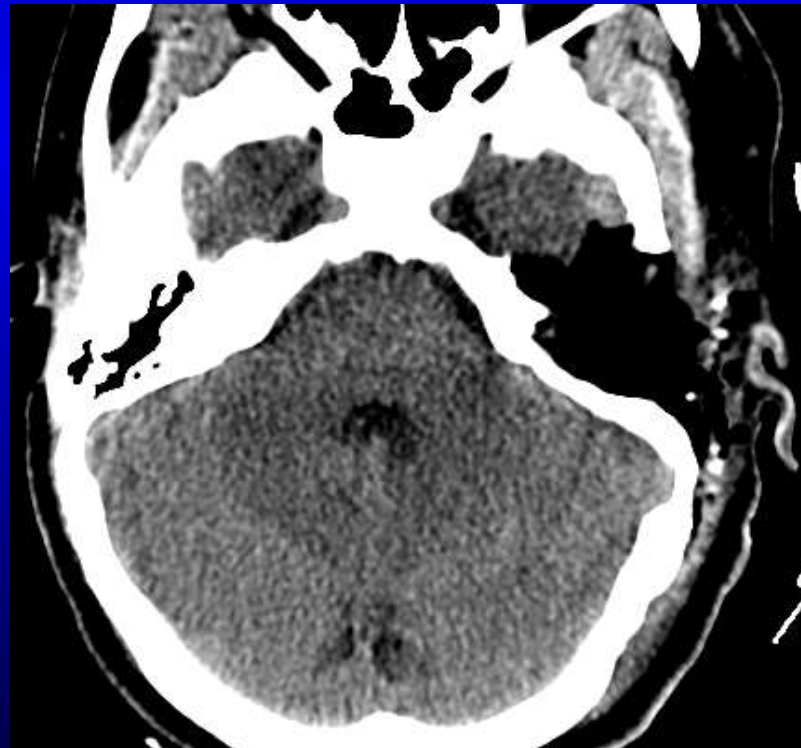CASE #1 – Recurrent FN palsy

- Radiological investigation - MRI



CASE #1 – Recurrent FN palsy

- **Surgery**
 - Removal via left TO approach with sural nerve graft
- **Post-operative CT scan**



November 23nd, 2017

138 Hands-on Course in LATERAL SKULL BASE SURGERY

November 20th-24th 2017

GRUPPO OTOLOGICO

Piacenza – Rome

Italy

