

November 22nd, 2017

138 Hands-on Course in LATERAL SKULL BASE SURGERY

November 20th-24th 2017

GRUPPO OTOLOGICO

Piacenza – Rome

Italy

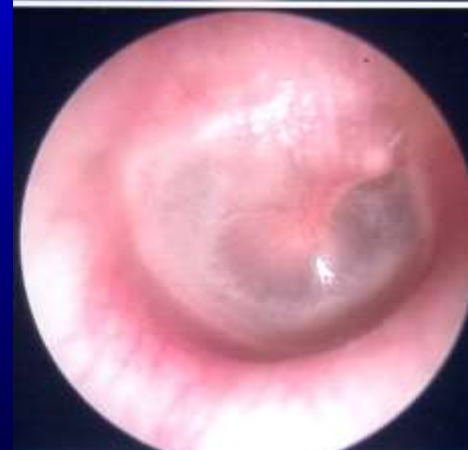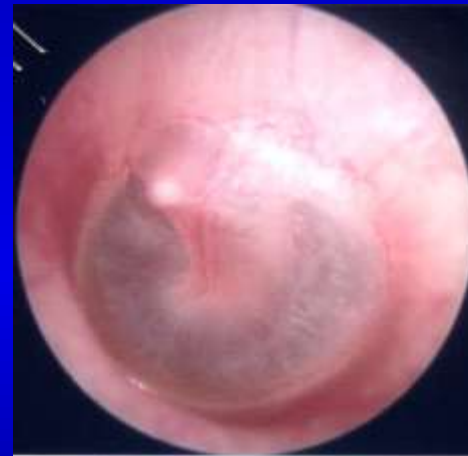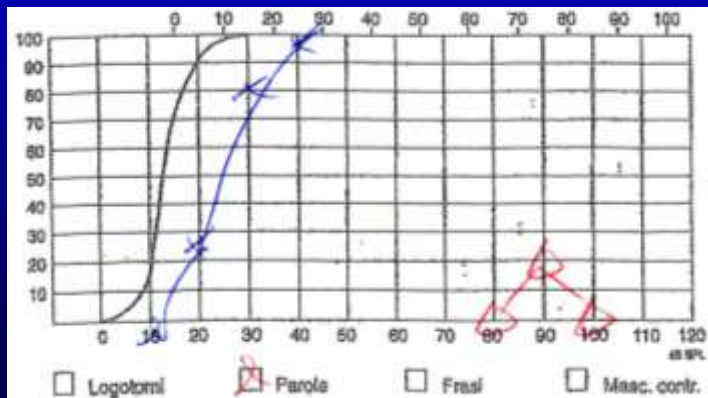
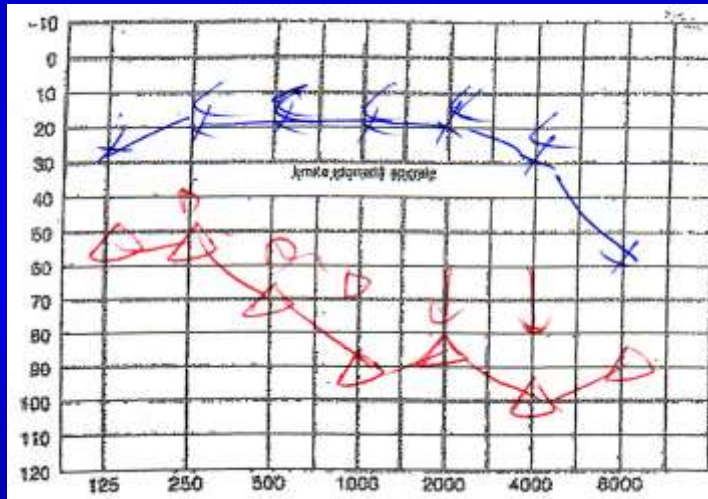


CASE #1 – Growing CPA tumor

- **Age** – 71 years
- **Sex** – Female
- **History**
 - Progressive right HL and tinnitus in the last 15 years
 - 2014: Right VS → F/U
 - Control MRI: tumor growth
 - No other CNs involvement
- **Otoscopy** – Normal

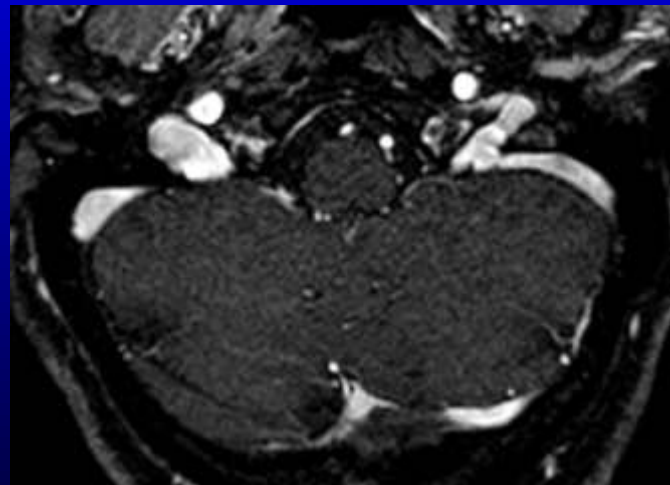
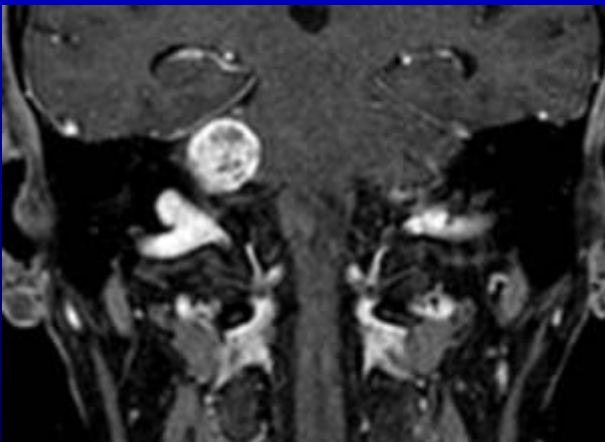
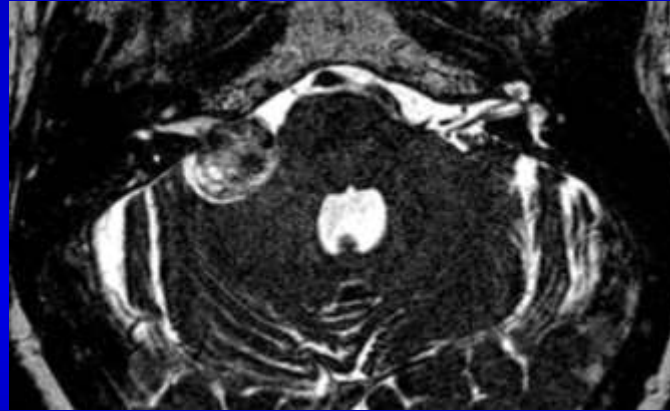
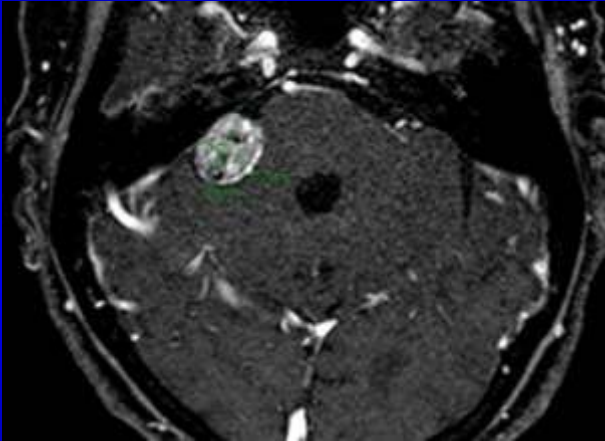
CASE #1 – Growing CPA tumor

- Hearing Tests & Otoscopy



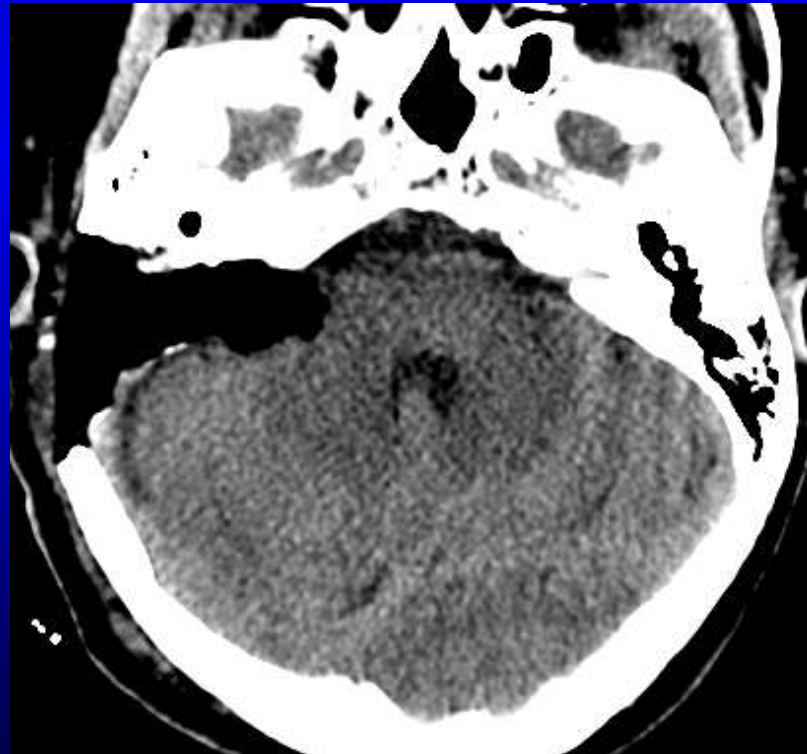
CASE #1 – Growing CPA tumor

- Radiological investigation - MRI



CASE #1 – Growing CPA tumor

- **Surgery**
 - Total removal via right TLA-TA approach with FN preservation
- **Post-operative CT scan**

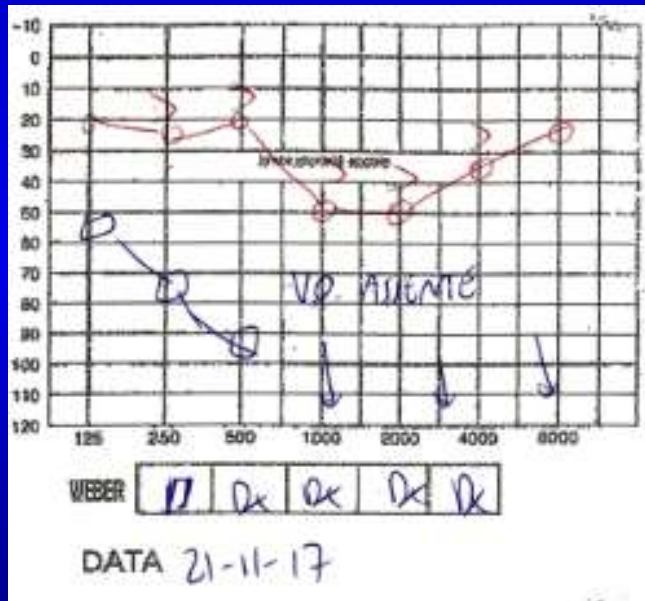


CASE #2 - Left Hemifacial spasm

- **Age** – 65 years
- **Sex** – Female
- **History**
 - Left HFS since 7 years ago
 - Medical treatment without symptoms
 - 08/2017: left SSHL (vertigo, tinnitus)

CASE #2 - Left Hemifacial spasm

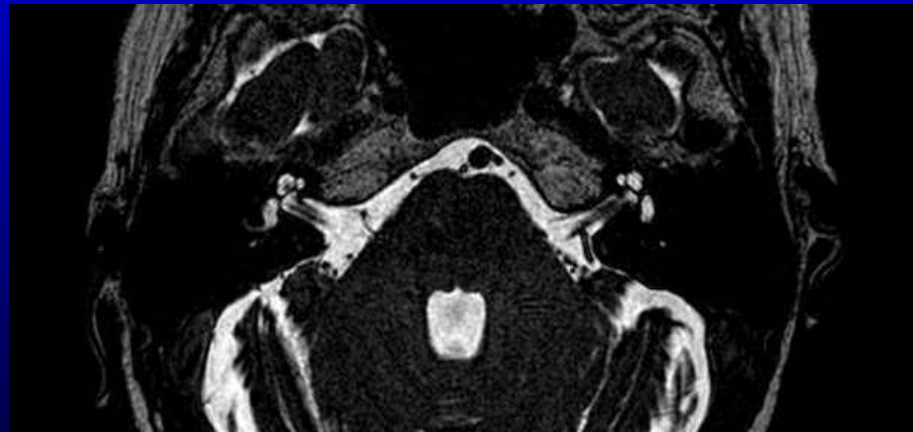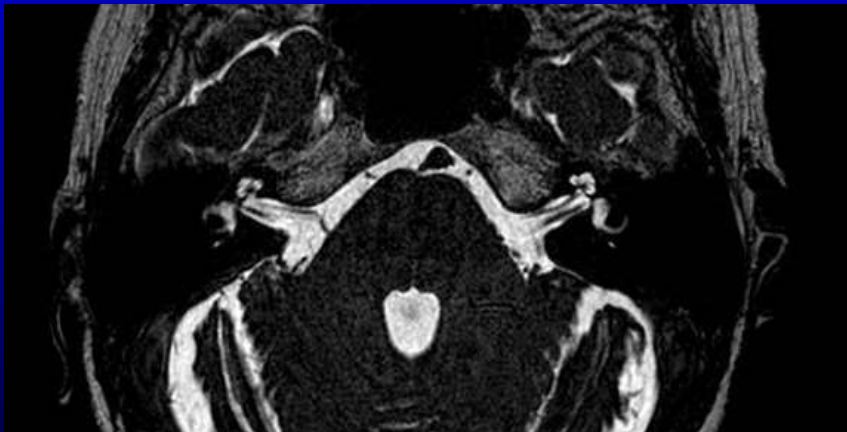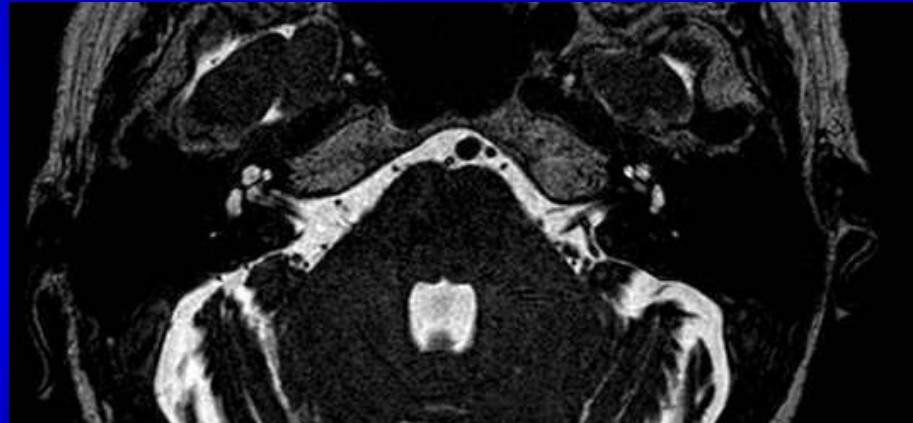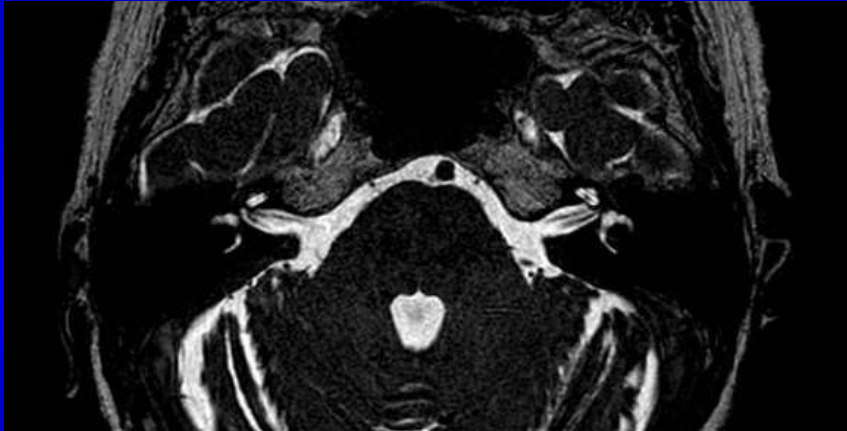- **Hearing Tests**



- **Otoscopy** – Normal
- **Other CNs** – Normal

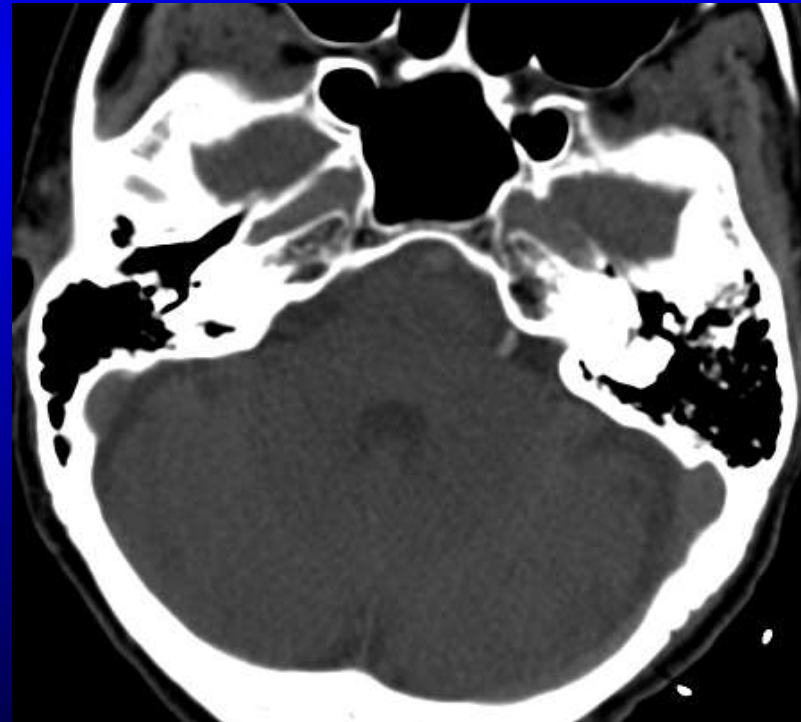
CASE #2 - Left Hemifacial spasm

- Radiological investigation - MRI



CASE #2 - Left Hemifacial spasm

- **Surgery**
 - Microvascular decompression (RS approach)
- **Post-operative CT scan**

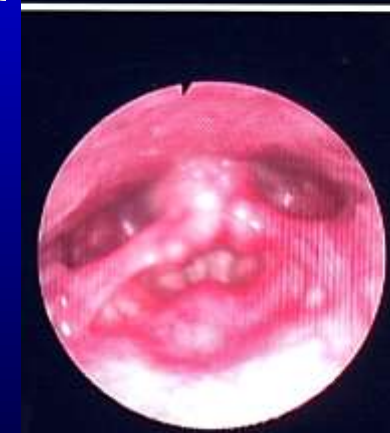
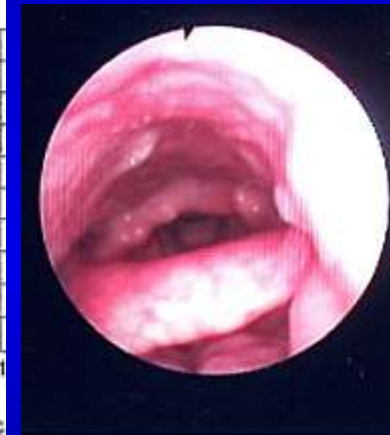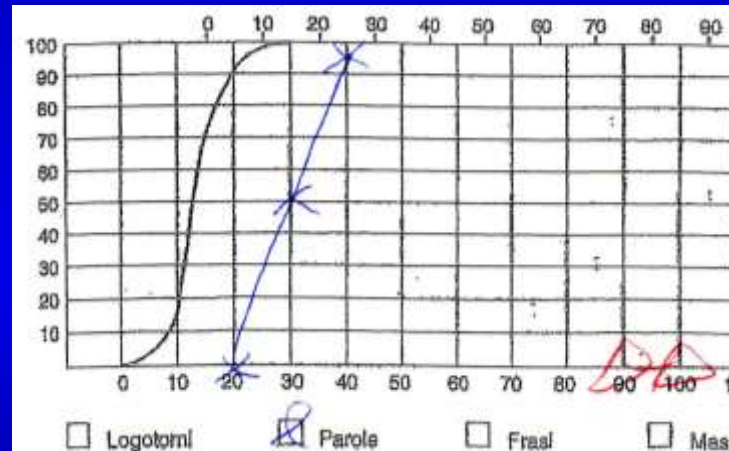
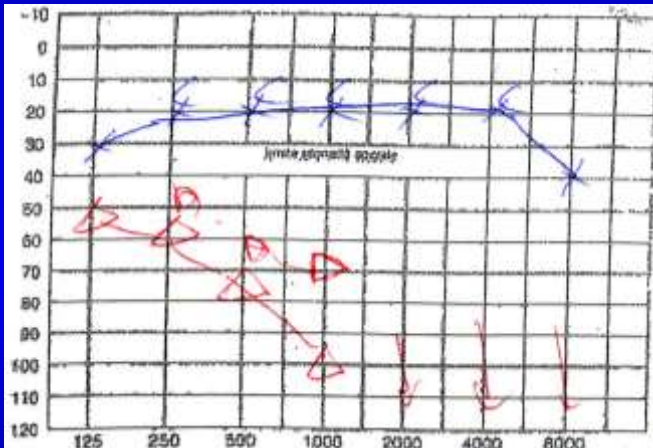


CASE #3 – Irradiated VS

- **Age** – 59 years
- **Sex** – Male
- **History**
 - 2016: diagnosed with right VS (HL)
 - Conventional RT (01/2017 – 02/2017)
 - Dizziness/disabling vertigo since then
 - No benefit from vestibular rehab

CASE #3 – Irradiated VS

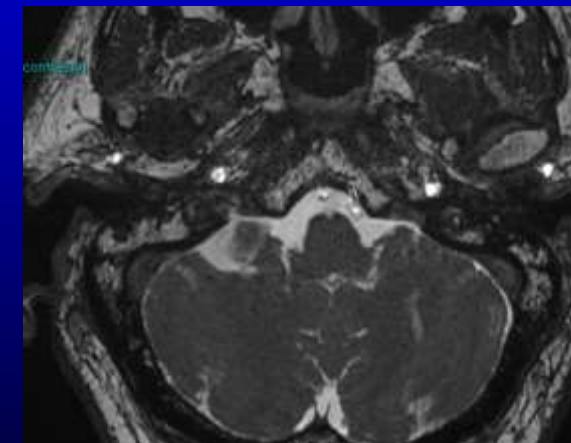
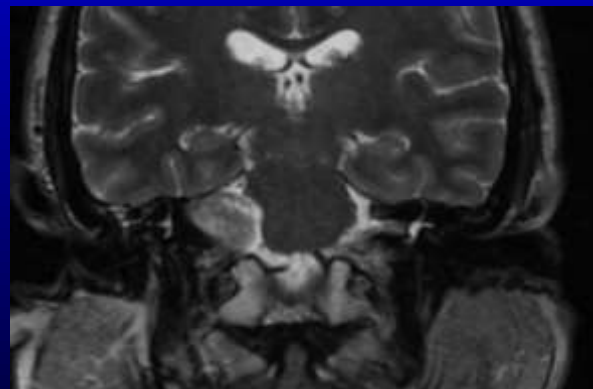
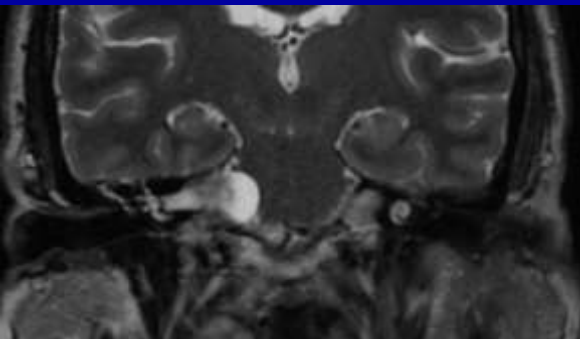
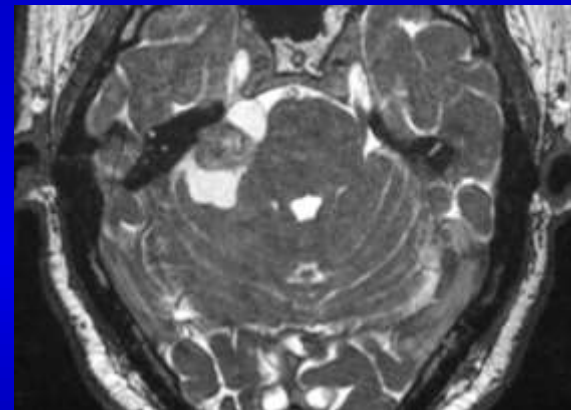
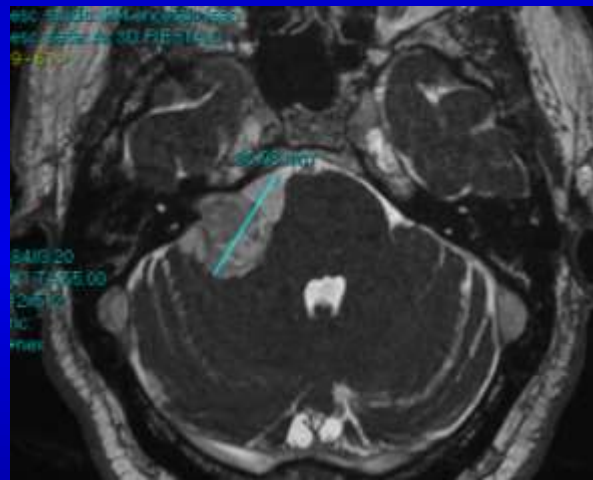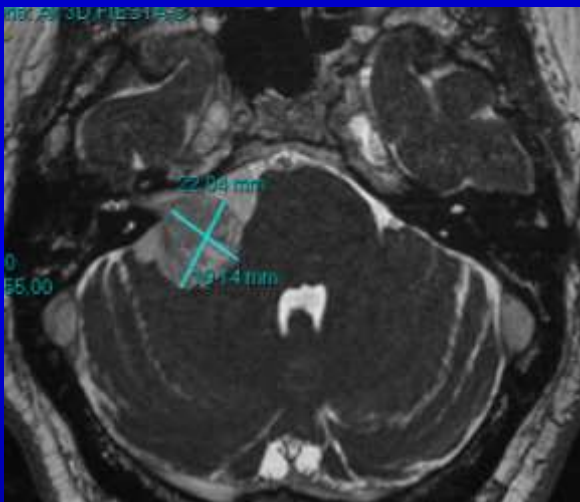
• Hearing Tests



- Otoloscopy – Normal
- Other CNs - Normal

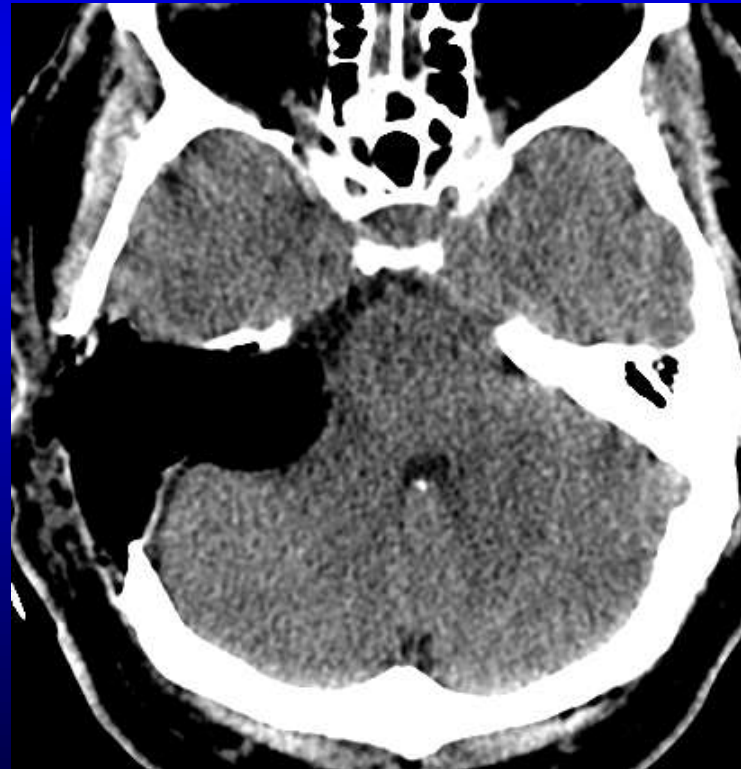CASE #3 – Irradiated VS

- Radiological investigation - MRI



CASE #3 – Irradiated VS

- **Surgery**
 - Total removal via right TLA-TA approach
- **Post-operative CT scan**

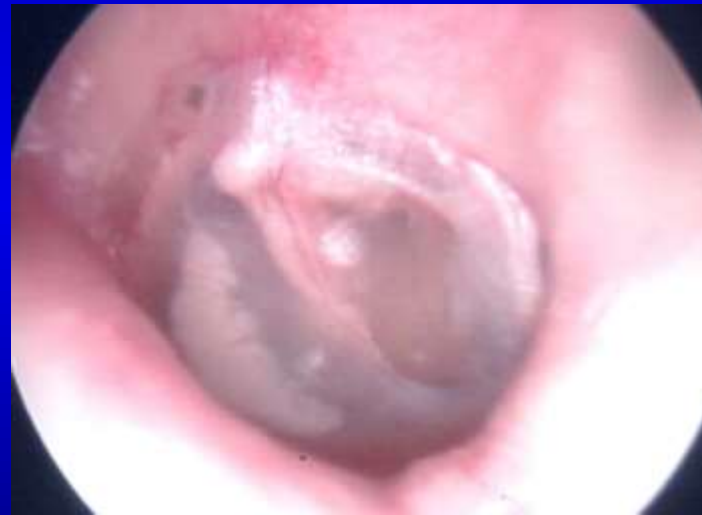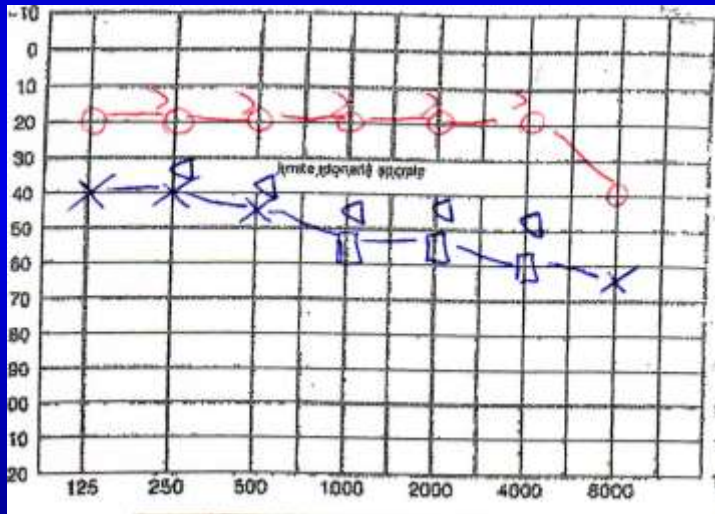


CASE #4 – Refractory MD

- **Age** – 52 years
- **Sex** – Male
- **History**
 - 2016: diagnosed with left MD
 - ITG on 07/2016 and 11/2016
 - After some months new attacks, impaired QoL

CASE #4 – Refractory MD

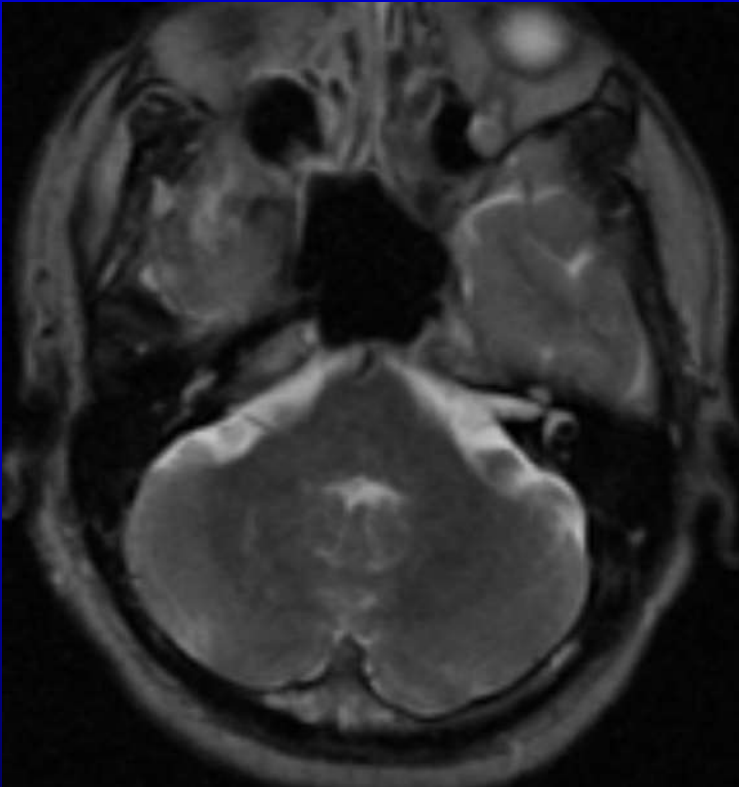
- **Hearing Tests & otoscopy**



- **Bedside examination** - Unilateral vestibular hypofunction
- **DHI** – 68 (severe)

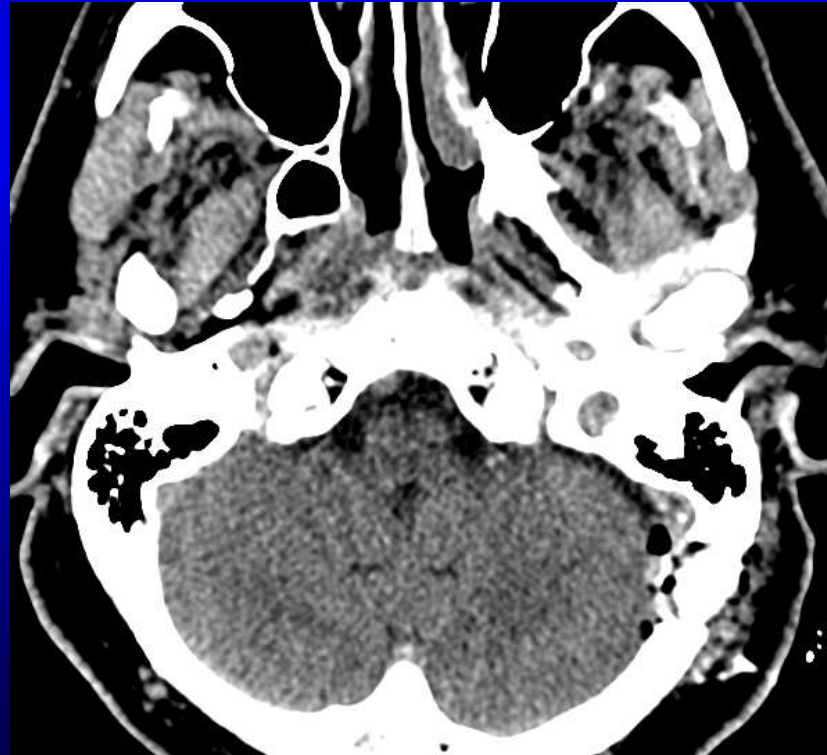CASE #4 – Refractory MD

- Radiological investigation - MRI



CASE #4 – Refractory MD

- **Surgery**
 - Left vestibular neurectomy (Retrosigmoid approach)
- **Post-operative CT scan**



November 22nd, 2017

138 Hands-on Course in LATERAL SKULL BASE SURGERY

November 20th-24th 2017

GRUPPO OTOLOGICO

Piacenza – Rome

Italy

